

Association of Third Molar Eruption and Frictional Keratosis - A Retrospective Study

Vaishnavi Sivakali Subramanian

*Saveetha Dental College and Hospitals,
Saveetha Institute of Medical and Technical Sciences,
Chennai- 77, India
Email id: 151501031.sdc@saveetha.com*

G.Maragathavalli

*Professor,
Department of Oral Medicine and Radiology
Saveetha Dental college and Hospitals,
Saveetha Institute of Medical and Technical Sciences,
Chennai-77, India
Email id : drgopalvalli@gmail.com*

Aravind Kumar S

*Professor,
Department of Orthodontics,
Saveetha Dental college and Hospitals,
Saveetha Institute of Medical and Technical Sciences,
Chennai-77, India
Email id : aravindkumar@saveetha.com*

Corresponding Author

G.Maragathavalli

*Professor,
Department of Oral Medicine and Radiology,
Saveetha Dental College and Hospitals,
Saveetha Institute of Medical and Technical Sciences,
162, PH Road, Chennai-600077,
Tamil Nadu, India
Email id : drgopalvalli@gmail.com*

Article Info**Volume 83****Page Number: 2858 – 2869****Publication Issue:****July-August 2020****Abstract:**

Frictional keratosis represents increased keratin production in response to chronic mechanical irritation. The retromolar pad and edentulous alveolar ridge are the most common sites of involvement due to trauma from food being crushed against the mucosa during mastication. A fractured tooth or rough restoration may lead to the development of frictional keratosis on the adjacent lateral tongue or buccal mucosa. These lesions do not undergo malignant change and should resolve after the source of irritation is eliminated. The aim of the study was to investigate the association of a third molar eruption with frictional keratosis among the patients of Saveetha dental college. A total of 200 patients with keratosis were taken into the study from Saveetha Dental College, Chennai. The data was collected from case sheets of patients who reported for various dental treatments between the period of June 2019 to March 2020 which consists of patients' demographic data, personal history, medical history, intra and extraoral findings and photographs which are taken with patients' concern. Chi square test was done using SPSS. The results showed 20-30 year old patients were seen maximum with all the reported clinical findings. This proportion decreases with increase in age groups. Maxillary third molars had maximum number of buccoverted teeth (18 - buccoverted 21% and sharp cusp 3%) (28- buccoverted 9.5% and sharp cusp 6.5%) and mandibular third molars were reported with maximum number of sharp cuspal tips (38-35% sharp cusp and 5% buccoverted)(48- 9% sharp cusp and 1.5% buccoverted). Within the limitations of the study, the results show that buccoverted third molars are the most common reason that causes frictional keratosis followed by sharp cuspal tips and cheek biting habits. However tobacco pouch keratosis is also seen among the patients.

Article History**Article Received: 06 June 2020****Revised: 29 June 2020****Accepted: 14 July 2020****Publication: 25 July 2020****Keywords:** *Buccoverted; Frictional Keratosis; Keratosis; Third Molar***INTRODUCTION**

With constant mechanical irritation in oral mucosa, there is increased production of keratin in mucosa. This leads to discrete white plaque with a rough corrugated surface and has blended margins with the adjacent mucosa. Factors such as fractured teeth, rough restoration or buccoverted third molar eruption may lead to the development of frictional keratosis on the adjacent lateral tongue or buccal mucosa (Sloan *et al.*, 2017) . Parafunctional habits where there is constant mechanical friction like rubbing, chewing or sucking of the oral mucosa against the teeth can also cause keratosis of the buccal mucosa, tongue and lip (Pinto, Haberland and Baker, 2014) . Depending on the degree of trauma, this can be minimal or extensive. The surface of the keratotic lesion can appear as

irregular tags which sometimes only involves the portion of mucosa which has undergone mechanical irritation, or can also be extensive involving the entire cheek and extending to the lips. Linea alba is the white keratotic line on the buccal mucosa along the occlusal plane. Linea alba can be either unilateral or bilateral and also varies in color intensity and thickness (Madani and Kuperstein, 2014; Pinto, Haberland and Baker, 2014) .

The retromolar pad, edentulous alveolar ridge and buccal mucosa are the most common sites of involvement of keratosis due to trauma from food being crushed against the mucosa during mastication (Sloan *et al.*, 2017) . Frictional keratosis does not transform into any malignant lesion and will resolve as soon as the source of irritation is eliminated

(Madani and Kuperstein, 2014; Müller, 2017b, 2018) However there are various misconception of frictional keratosis being described or diagnosed as leukoplakia. The clinical findings of frictional keratosis can be of an ill-defined area of gray or white papules and plaques which may be associated with erosions and ulcers if the bite trauma is extensive. The affected area may appear with shredded keratin and peeling. Whereas in homogenous leukoplakia appears as uniformly white and the surface is flat or slightly wrinkled and in non homogeneous leukoplakias appears as a uniform, thin white area altering or not with normal mucosa. The speckled type is a white and red lesion, with a predominantly white surface. Verrucous leukoplakia has an elevated, proliferative or corrugated surface appearance. The nodular type has small polypoid outgrowths, rounded predominantly white excrescences (Warnakulasuriya, Johnson and van der Waal, 2007). Generally, the clinical findings are adequate in determining the etiology of the white lesions and do not require confirmatory biopsy.

Previously our team had conducted numerous clinical trials (Misra *et al.*, 2015; Steele *et al.*, 2015; Chellammal and Dharman, 2016; Subashri and Uma Maheshwari, 2016; Venugopal and Maheshwari, 2016; Chaitanya *et al.*, 2017; Maheshwari *et al.*, 2018) and lab animal studies (Dharman and Muthukrishnan, 2016; Muthukrishnan, Kumar and Ramalingam, 2016; Rohini and Jayanth Kumar, 2017; Chaitanya *et al.*, 2018; Muthukrishnan and Warnakulasuriya, 2018) and in vitro studies over the past 5 years. (Umamaheswari, 2014; Muthukrishnan and Bijai Kumar, 2017; Subha and Arvind, 2019)

Therefore this retrospective study was carried out to investigate the association of a third molar eruption with frictional keratosis among the patients of Saveetha dental college.

MATERIALS AND METHOD

Study setting

This study is a university setting study. Case records of patients who had visited the university hospital between June 2019 to March 2020 were analysed and those patients with keratosis were included in the study. Prior to the study, ethical approval was obtained from the Institutional Ethical Committee. (Ethical approval number: SDC/SIHEC/2020/DIASDATA/0619-0320).

Sampling

It is a retrospective study in which totally 200 case sheets of patients with keratosis were analysed. A non probability consecutive sampling method was followed. Cross verification of data for error was done by photographic evaluation and verified by additional reviewers. All patients with frictional keratosis were evaluated to minimize sampling bias. Any patient with incomplete data was not included in the sample chosen for the study

Data collection/Tabulation

Data of keratosis and the presence of a third molar were collected retrospectively from the case records of patients. Inclusion criteria included Patients above 20 year age groups and with all keratotic lesions. Exclusion criteria: Patients with incomplete data and below 20 year age groups were excluded from the study. Data entered in MS excel was imported to SPSS version 20.0 for statistical analysis.

Statistical analysis

IBM SPSS 20.0 software was used for data analysis. Independent variables include - age, gender. Dependent variables include presence or absence of a third molar. Descriptive and inferential statistics were used. Descriptive statistics included the frequency of distribution of patients' age, gender and inferential test included the Chi-square test to statistically analyse the

association of gender and age group with presence of third molars causing frictional keratosis.

RESULTS AND DISCUSSION

Patients who were diagnosed with keratotic lesions were selected for this study. Out of 200 patients, 20-30

year old patients were maximum (35%), followed by 31-40 year old patients (27.5%), 41-50 year old patients (24.0 %), 51-60 year old patients (11.0%). Patients above 61 year old were minimal (2.50%) (Figure 1).

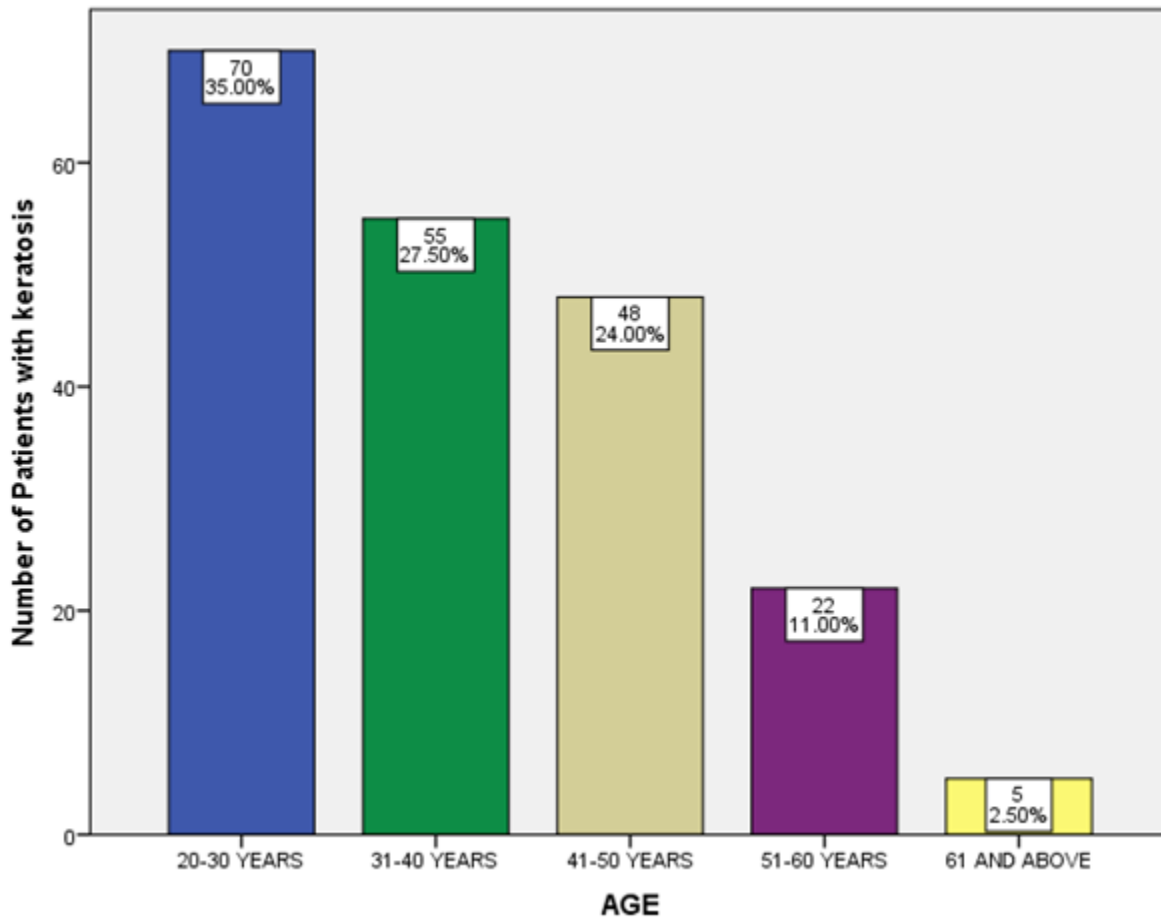


Figure1: Bar graph shows the distribution of patients with keratotic lesions based on their age. X-axis depicts the age of the patients and Y axis represents the number of patients. The age was colour coded as blue (20-30 years), green (30-40 years), beige (41-50 years), violet (51-60 years) and yellow (61 and above years). The graph shows that the majority of the patients were among 20-30 year age group and 61 and above age group were the least.

Among these patients maximum frequency were seen in male with 92% of the population and females were only 8% (Figure 2).

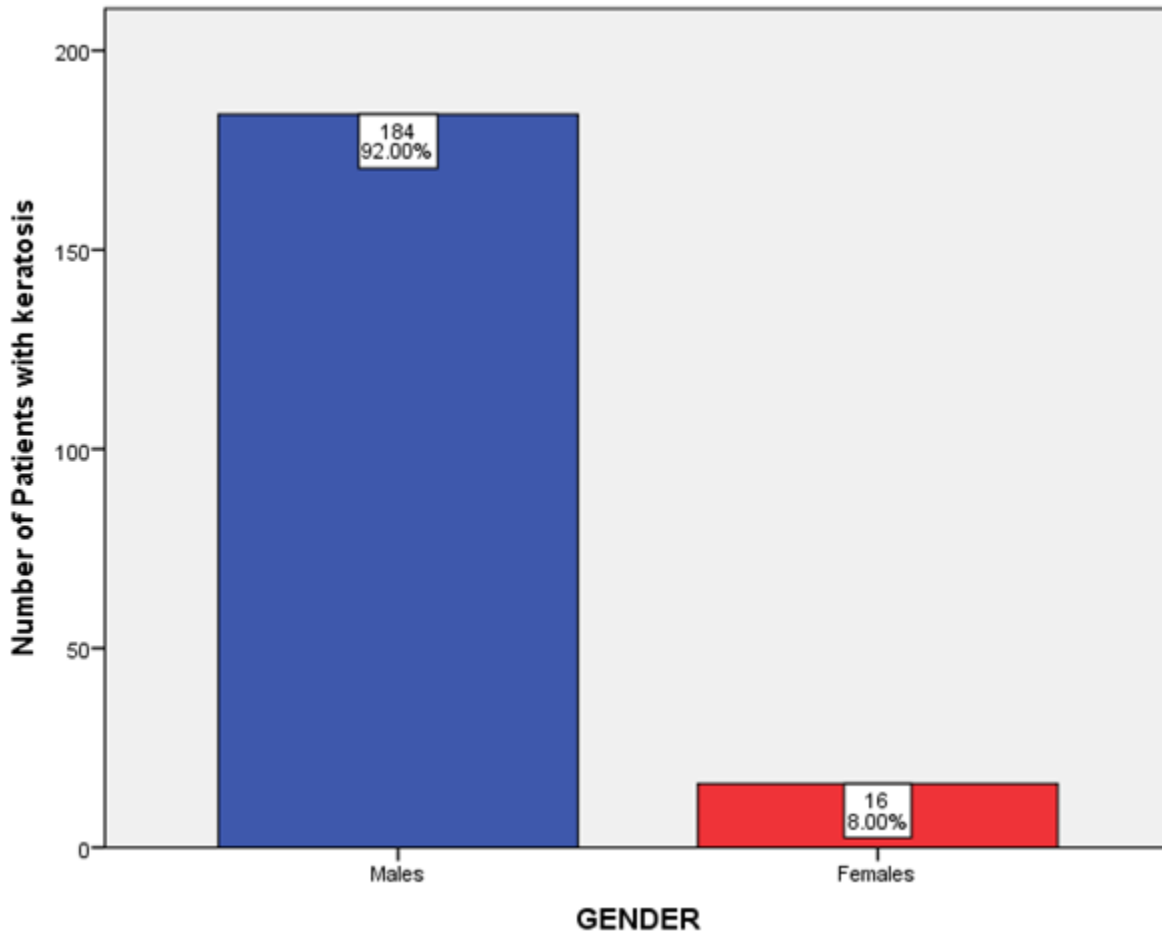


Figure 2: Bar graph showing the distribution of patients with keratotic lesions based on their gender. X axis depicts the gender of patients. Y axis represents the percentage of students. The graph shows that the majority of the patients were males compared to females.

Third molars are often known to cause keratosis of oral mucosa than the other teeth (tooth number 18 - 24%, tooth number 28-16%, tooth number 38-8.5% and tooth number 48-10.5%). Maxillary right third molars (18) were most common (Figure 3).

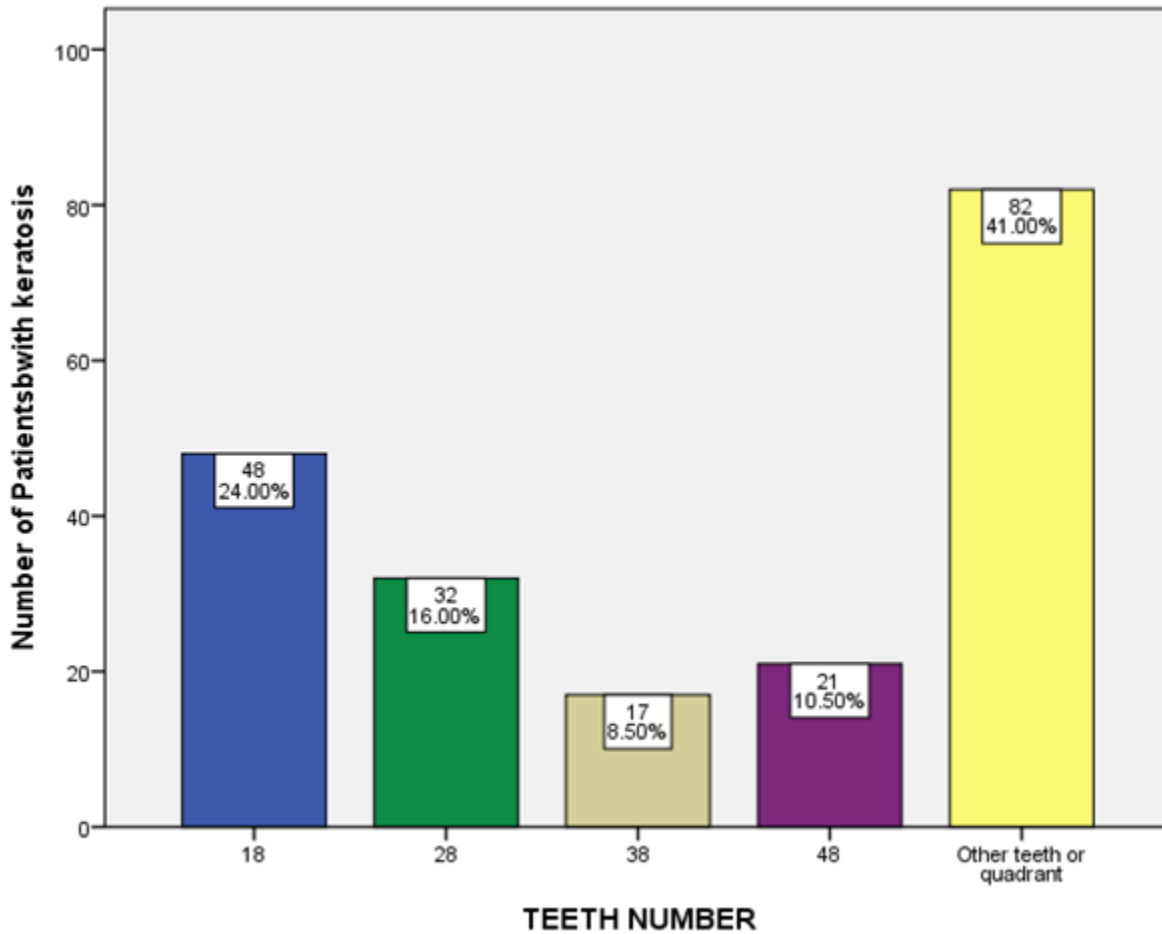
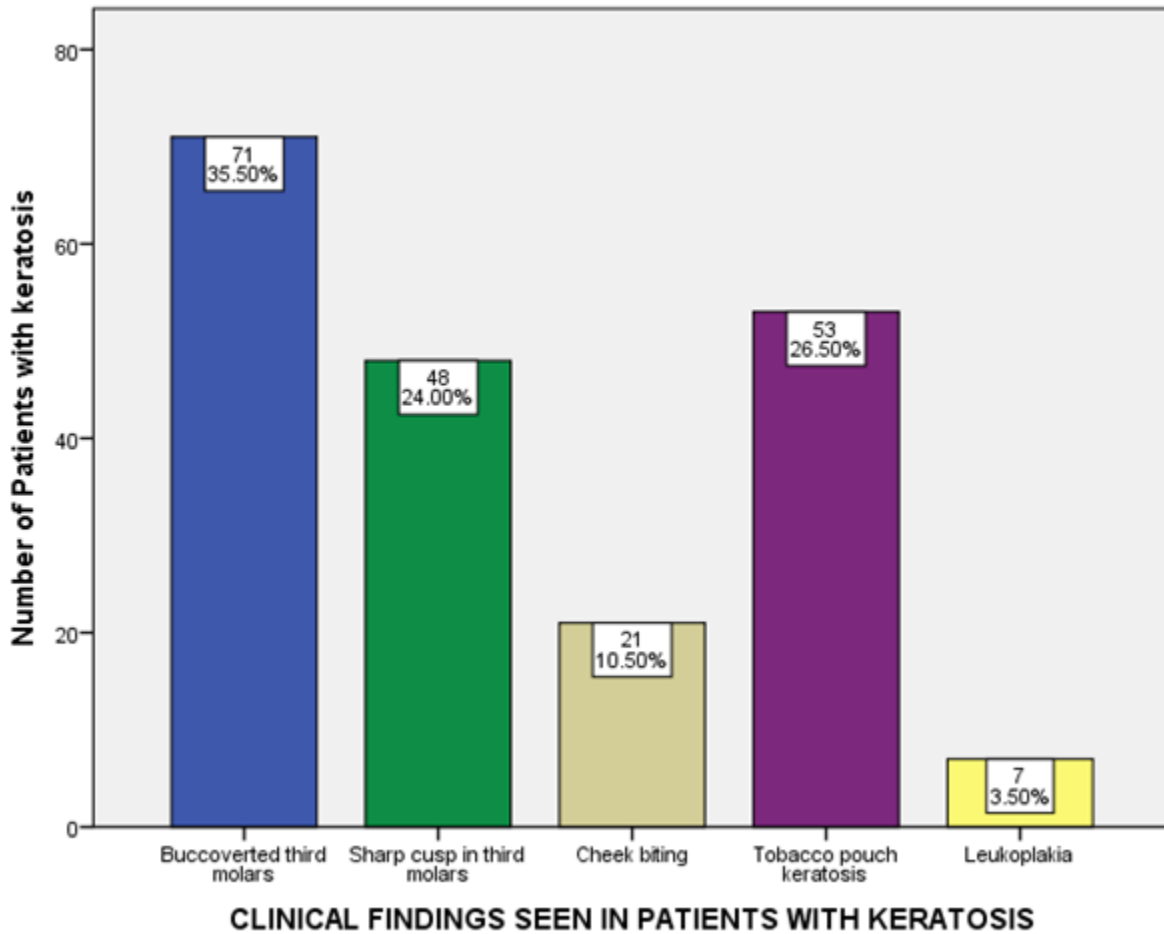


Figure 3: Bar graph represents the distribution of patients with keratotic lesion based on the teeth number. X-axis represents the teeth number (18-Blue, 28-Green, 38-Beige, 48-Violet, Other teeth or quadrant-Yellow) and Y-axis represents the number of patients. The graph shows that third molars

35.5% of the patients had buccoverted third molars which were the primary source of constant irritation causing frictional keratosis. Whereas 24% of the patient's third molar had sharp cuspal tips and 10.5% of the patients had cheek biting habit. These were most common clinical findings reported for frictional

keratosis. Apart from frictional keratosis, other keratotic lesions were also seen. 26.5% of the patients had tobacco pouch keratosis. Whereas 3.5% patients were suspected with leukoplakia like lesions and they were advised to undergo biopsy for confirmatory diagnosis (Figure 4).



were most common cause for keratosis in patients.

Figure 4: Bar graph represents the distribution of patients with keratotic lesions based on their clinical findings. X-axis represents the clinical findings (Buccoverted third molars-Blue, Sharp cusp in third molars-Green, Cheek biting-Beige, Tobacco pouch keratosis-Violet, Leukoplakia-Yellow) and Y-axis represents the number of patients. The graph shows that buccoverted third molars were most common in patients.

Association of age and the clinical findings seen in patients with keratosis shows that buccoverted third molars were most common in all age groups. However 20-30 year old patients were seen maximum with all the reported clinical findings. This proportion

decreases with increase in age groups. However tobacco pouch keratosis was also commonly reported among all age groups and was predominant in 20-30 year old patients (Figure 5)

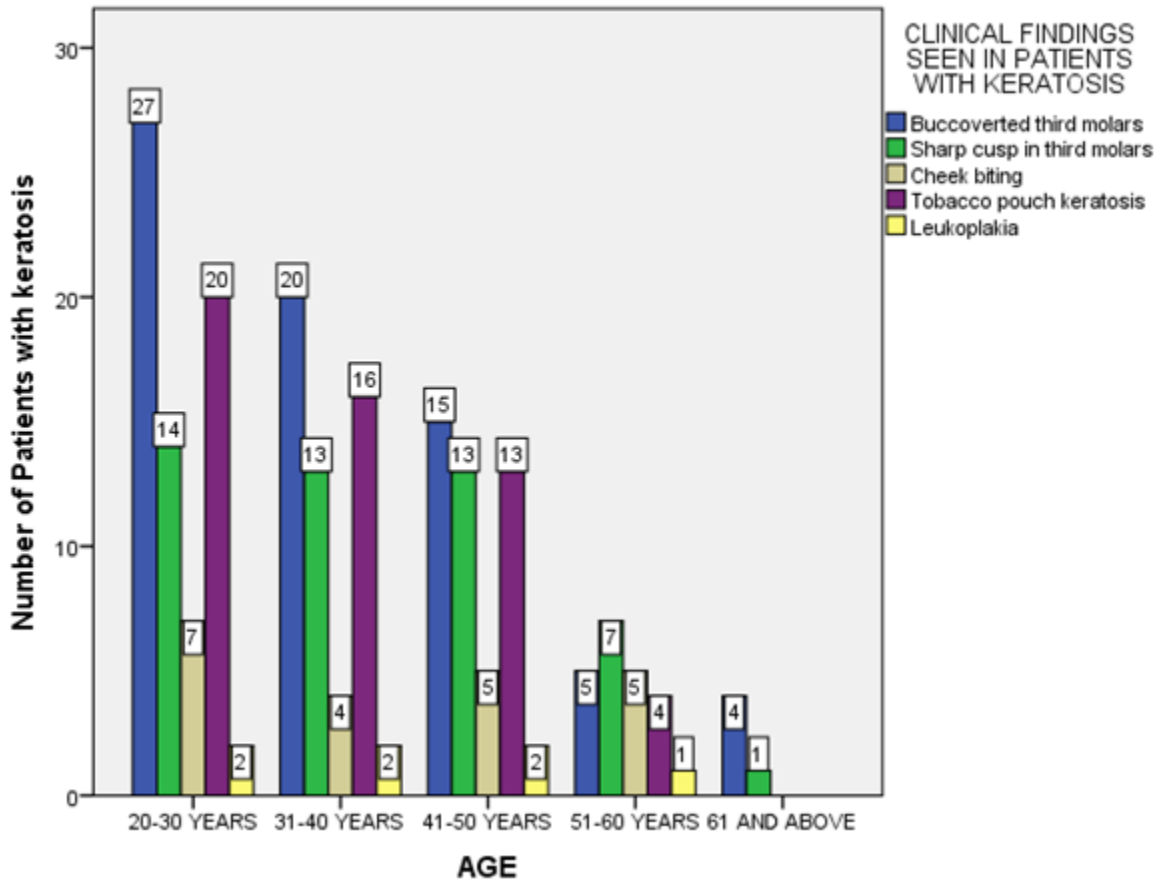


Figure 5: Bar graph shows the association between the clinical findings of the patients with keratosis and their age. X axis depicts the age. Y axis represents the number of patients with keratotic lesions. The graph shows that the 20-30 year old patients were most common with all the findings (Buccoverted third molars-Blue, Sharp cusp in third molars-Green, Cheek biting-Beige, Tobacco pouch keratosis-Violet, Leukoplakia-Yellow). Chi square test was done. p value- 0.686 (>0.05), hence statistically insignificant.

p value- 0.686 (>0.05). Figure 6

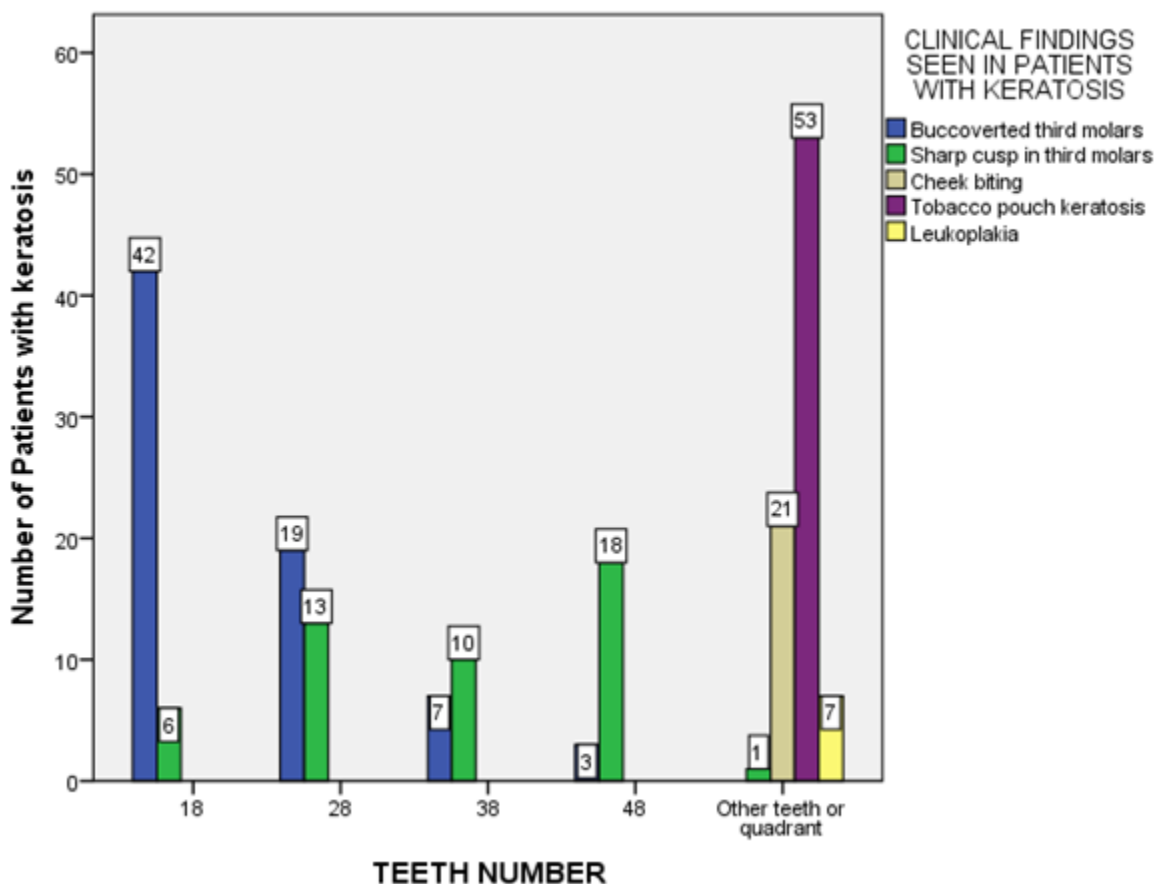


Figure 6: Bar graph shows the association between the clinical findings of the patients with keratosis and their teeth number. X axis depicts the teeth number. Y axis represents the number of patients with keratotic lesions. The graph shows that the maxillary third molars were most common with buccoverted teeth among which 18 were the maximum. Whereas mandibular third molars were common with sharp cuspal tips among which 48 were maximum. However, tobacco pouch keratosis was also commonly seen in relation to other teeth or quadrant (Buccoverted third molars-Blue, Sharp cusp in third molars-Green, Cheek biting-Beige, Tobacco pouch keratosis-Violet, Leukoplakia-Yellow). Chi square test was done. p value- 0.000 (<0.05), hence statistically significant.

shows the association of teeth and the clinical findings. Maxillary third molars had maximum number of buccoverted teeth (18 - buccoverted 21% and sharp cusp 3%) (28- buccoverted 9.5% and sharp cusp 6.5%) and mandibular third molars were reported with maximum number of sharp cuspal tips (38-35% sharp cusp and 5% buccoverted)(48- 9% sharp cusp and 1.5% buccoverted) p value- 0.000 (<0.05).

There are other regions in oral cavity such as retromolar pad and edentulous alveolar ridge that equally exhibit benign keratosis as the area is susceptible to both masticatory forces, occlusal trauma or ill-fitting dentures or other dental appliances (Chi *et al.*, 2007; Natarajan and Woo, 2008). Frictional keratosis in the alveolar ridge usually is surfaced by orthokeratin with a slightly irregular or corrugated

surface. An evident granular cell layer is seen. The epithelium may show acanthosis and epithelial rete may be elongated or atrophic (Chi *et al.*, 2007; Natarajan and Woo, 2008). Similar to frictional keratosis of the buccal mucosa and tongue, a small amount of inflammatory cells is present. When limited clinical information is available about frictional keratosis of the alveolar ridge and gingiva in tooth-bearing areas proper care should be made in making a diagnosis. Toothbrush trauma is a common etiology of keratotic lesions of the gingiva. However, most traumatized gingiva of the tooth bearing area expresses erythema, ulceration, or other reactive lesions such as pyogenic granuloma. The clinical findings alone are difficult to distinguish between reactive keratosis and oral potentially malignant disorders. There is both clinical and histological similarity in the features of benign keratosis and keratosis associated with proliferative verrucous leukoplakia (PVL) which is a recognized oral potentially malignant disorder (Chi *et al.*, 2007; Müller, 2017a). But of unknown etiology, PVL is associated with high recurrence and malignant transformation rates. The gingiva is the most common site for PVL (Pentenero *et al.*, 2014).

Apart from mechanical irritation, there are keratosis caused by chemical irritation. The oral mucosa is exposed to a wide variety of external chemical irritants. Chemical products such as toothpastes, mouthwashes, and dental restorations can result in oral mucosal injury. But the contact period of these products with oral mucosa is very short or saliva dilutes and buffers the irritants reducing the potential for an adverse reaction. However, with increased concentration, duration, or frequency of the chemical the patient may have a reaction and develop keratosis, ulcerations, vesicles, erythema, edema or a combination of these (Kowitz *et al.*, 1990).

No significant literature opposing the consensus was found. The study being conducted within an institution does not represent all ethnic groups and populations. Hence the study can not be generalized. Also subjective errors bias may creep in. Hence a study including all patients across the country in a similar study setup can provide better accurate results.

CONCLUSION

Within the limitations of the study, the results show that buccoverted third molars (35.50%) is the most common reason that causes frictional keratosis followed by sharp cuspal tips and cheek biting habits. However tobacco pouch keratosis is also seen among the patients. Therefore from this study we can conclude that third molar eruption pattern is evidently associated with frictional keratosis

AUTHOR CONTRIBUTIONS

First author, Vaishnavi Sivakali Subramanian performed the data collection by reviewing patient details, filtering required data, analysing and interpreting statistics and contributed to manuscript writing. Second author, Dr. Maragathavalli contributed to conception of study title, study design, analysed the collected data, statistics and interpretation and also critically revised the manuscript. Third author, Dr. Aravind Kumar.S participated in the study and revised the manuscript. All the three authors have discussed the results and contributed to the final manuscript.

ACKNOWLEDGEMENTS

The authors sincerely thanked Saveetha Dental College and Hospitals, Saveetha Institutes of Medical and Technical Sciences, Saveetha University, Chennai for all the support throughout the study.

CONFLICT OF INTEREST

There were no potential conflicts of interest as declared by authors.

REFERENCES

1. Chaitanya, N. C. *et al.* (2017) 'Role of Vitamin E and Vitamin A in Oral Mucositis Induced by Cancer Chemo/Radiotherapy- A Meta-analysis', *Journal of clinical and diagnostic research: JCDR*, 11(5), pp. ZE06–ZE09.
2. Chaitanya, N. C. *et al.* (2018) 'An Insight and Update on the Analgesic Properties of Vitamin C', *Journal of pharmacy & bioallied sciences*, 10(3), pp. 119–125.
3. Chellammal, M. R. and Dharman, S. (2016) 'Assessment of Enamel Defects in Patients Visiting Saveetha Dental College, Chennai: A Pilot Study', *Research journal of pharmaceutical, biological and chemical sciences. RJPBCS RESEARCH JOURNAL PHARMACEUTICAL, BIOLOGICAL & CHEMICAL SCIENCES ...*, 7(3), pp. 995–1001.
4. Chi, A. C. *et al.* (2007) 'Is alveolar ridge keratosis a true leukoplakia?: A clinicopathologic comparison of 2,153 lesions', *Journal of the American Dental Association*, 138(5), pp. 641–651.
5. Dharman, S. and Muthukrishnan, A. (2016) 'Oral mucous membrane pemphigoid - Two case reports with varied clinical presentation', *Journal of Indian Society of Periodontology*, 20(6), pp. 630–634.
6. Kowitz, G. *et al.* (1990) 'The effects of tartar-control toothpaste on the oral soft tissues', *Oral surgery, oral medicine, and oral pathology*, 70(4), pp. 529–536.
7. Madani, F. M. and Kuperstein, A. S. (2014) 'Normal variations of oral anatomy and common oral soft tissue lesions: evaluation and management', *The Medical clinics of North America*, 98(6), pp. 1281–1298.
8. Maheswari, T. N. U. *et al.* (2018) 'Salivary micro RNA as a potential biomarker in oral potentially malignant disorders: A systematic review', *Ci ji yi xue za zhi = Tzu-chi medical journal*, 30(2), pp. 55–60.
9. Misra, S. R. *et al.* (2015) 'Metastatic hepatocellular carcinoma in the maxilla and mandible, an extremely rare presentation', *Contemporary clinical dentistry*, 6(Suppl 1), pp. S117–21.
10. Müller, S. (2017a) 'Oral lichenoid lesions: distinguishing the benign from the deadly', *Modern pathology: an official journal of the United States and Canadian Academy of Pathology, Inc*, 30(s1), pp. S54–S67.
11. Müller, S. (2017b) 'Update from the 4th Edition of the World Health Organization of Head and Neck Tumours: Tumours of the Oral Cavity and Mobile Tongue', *Head and neck pathology*, 11(1), pp. 33–40.
12. Müller, S. (2018) 'Oral epithelial dysplasia, atypical verrucous lesions and oral potentially malignant disorders: focus on histopathology', *Oral surgery, oral medicine, oral pathology and oral radiology*, 125(6), pp. 591–602.
13. Muthukrishnan, A. and Bijai Kumar, L. (2017) 'Actinic cheilosis: early intervention prevents malignant transformation', *BMJ case reports*, 2017. doi: 10.1136/bcr-2016-218654.

14. Muthukrishnan, A., Kumar, L. B. and Ramalingam, G. (2016) 'Medication-related osteonecrosis of the jaw: a dentist's nightmare', *BMJ Case Reports*, p. bcr2016214626. doi: 10.1136/bcr-2016-214626.
15. Muthukrishnan, A. and Warnakulasuriya, S. (2018) 'Oral health consequences of smokeless tobacco use', *The Indian journal of medical research*, 148(1), pp. 35–40.
16. Natarajan, E. and Woo, S.-B. (2008) 'Benign alveolar ridge keratosis (oral lichen simplex chronicus): A distinct clinicopathologic entity', *Journal of the American Academy of Dermatology*, 58(1), pp. 151–157.
17. Pentenero, M. *et al.* (2014) 'Oral proliferative verrucous leukoplakia: are there particular features for such an ambiguous entity? A systematic review', *The British journal of dermatology*, 170(5), pp. 1039–1047.
18. Pinto, A., Haberland, C. M. and Baker, S. (2014) 'Pediatric soft tissue oral lesions', *Dental clinics of North America*, 58(2), pp. 437–453.
19. Rohini, S. and Jayanth Kumar, V. (2017) 'Incidence of dental caries and pericoronitis associated with impacted mandibular third molar-A radiographic study', *Research Journal of Pharmacy and Technology*, p. 1081. doi: 10.5958/0974-360x.2017.00196.2.
20. Sloan, P. *et al.* (2017) 'Malignant surface epithelial tumours: squamous cell carcinoma', *WHO classification of tumours of the head and neck, 4th edn. IARC Press, Lyon.*
21. Steele, J. C. *et al.* (2015) 'World Workshop on Oral Medicine VI: an international validation study of clinical competencies for advanced training in oral medicine', *Oral Surgery, Oral Medicine, Oral Pathology and Oral Radiology*, pp. 143–151.e7. doi: 10.1016/j.oooo.2014.12.026.
22. Subashri, A. and Uma Maheshwari, T. N. (2016) 'Knowledge and attitude of oral hygiene practice among dental students', *Research Journal of Pharmacy and Technology*, p. 1840. doi: 10.5958/0974-360x.2016.00375.9.
23. Subha, M. and Arvind, M. (2019) 'Role of magnetic resonance imaging in evaluation of trigeminal neuralgia with its anatomical correlation', *Biomedical and Pharmacology Journal*, 12(1), pp. 289–296.
24. Umamaheswari, T. N. (2014) 'Salivary biomarkers in oral leukoplakia-a review', *International journal of pharma and bio sciences*, 6(5), pp. 3014–3018.
25. Venugopal, A. and Maheswari, T. N. U. (2016) 'Expression of matrix metalloproteinase-9 in oral potentially malignant disorders: A systematic review', *Journal of Oral and Maxillofacial Pathology*, p. 474. doi: 10.4103/0973-029x.190951.
26. Warnakulasuriya, S., Johnson, N. W. and van der Waal, I. (2007) 'Nomenclature and classification of potentially malignant disorders of the oral mucosa', *Journal of oral pathology & medicine: official publication of the International Association of Oral Pathologists and the American Academy of Oral Pathology*, 36(10), pp. 575–580.