

Evaluation of Etiology of Discoloration, Site of Discoloured Tooth and Outcomes of Different Techniques used for Vital Tooth Bleaching- A Retrospective Analysis

Running title : Evaluation of etiology of discoloration, discoloured tooth and outcomes of different techniques in vital tooth bleaching

Madhura Deshmukh

*Department of Prosthodontics and Implantology
Saveetha Dental College And Hospitals
Saveetha Institute Of Medical And Technical Sciences
Saveetha University
Chennai-600077, Tamilnadu, India*

Nabeel Ahmed

*Senior lecturer
Department of Prosthodontics and Implantology
Saveetha Dental College And Hospitals
Saveetha Institute Of Medical And Technical Sciences
Saveetha University
Chennai-600077, Tamilnadu, India
Email: nabeel.5610@gmail.com*

CORRESPONDING AUTHOR:

Nabeel Ahmed

*Senior lecturer
Department of Prosthodontics and Implantology
Saveetha Dental College And Hospitals
Saveetha Institute Of Medical And Technical Sciences
Saveetha University
Chennai-600077, Tamilnadu, India
Email: nabeel.5610@gmail.com*

Article Info**Volume 83****Page Number: 2800 – 2813****Publication Issue:****July-August 2020****Abstract:**

Smile is a curve that sets everything straight but a healthy smile needs good dental care. The appearance of the dentition is paramount to a large population seeking dental treatment and often the first evidence of variation from normal in human dentition is an observable difference in the color of the teeth. A thorough knowledge of the etiology of tooth staining is of prime importance to dental practitioners in order to reach a correct diagnosis. The purpose of this study was to assess the etiology, discoloured surfaces and outcomes of different techniques in terms of patient satisfaction for the management of vital bleaching. A total of 31 case sheets were retrospectively analysed from the university database. It was found that Fluorosis was the most prevalent etiology in about 74.19%, Conventional technique was the most prevalent technique in about 83.87% and Upper anteriors were the most prevalent affected area in about 70.97%. It was also found that in both 16-25 yrs and 26-45 yrs age groups, fluorosis was the most prevalent etiology. In 46+ yrs, both fluorosis and stains were equally prevalent, p value-0.102 ($p>0.05$). It was found that fluorosis was the prevalent etiology in both males (64.52%) and females (9.68%), p -value: 0.395 ($p>0.05$). For all sites, conventional technique is the most preferred technique, p -value: 0.751 ($p>0.05$). The outcome for both Conventional and Power bleach techniques had prevalence of satisfaction, p -value: 0.342 ($p>0.05$). Within the limitations of the study, we conclude that fluorosis was the most prevalent etiology for vital tooth discoloration. The discoloration of vital teeth was commonly presented in the upper anterior area followed by both upper and lower anteriors. Outcomes for conventional technique were more satisfactory than thermocatalytic.

Keywords: Aesthetics, Tooth discoloration, Vital Bleaching.**Article History****Article Received: 06 June 2020****Revised: 29 June 2020****Accepted: 14 July 2020****Publication: 25 July 2020****INTRODUCTION:**

Awareness and demand for aesthetic smiles has grown amongst the population over the last few years. Tooth discoloration is a common dental finding which is associated with clinical and aesthetic problems (Ahmed 2017). Discoloured teeth especially in the anterior region are a considerable cosmetic impairment.

Tooth discolouration varies in various aspects such as etiology, appearance, localization, severity and also adhesion to tooth structure. Detailed clinical examination and details of the patient's oral hygiene practices, dietary habits, and history of exposure to chemicals, trauma, and infection are essential to reach a final diagnosis.

The causes for tooth discoloration can be classified according to the location of the stains, either as extrinsic or intrinsic (Hattab, Qudeimat, and Al-Rimawi 1999), (Sulieman 2005). Extrinsic

discoloration lies on the tooth surface or within the acquired pellicle. The intrinsic discoloration occurs when the chromogens are deposited within the bulk of the tooth, which maybe of local or systemic origin (Vogel 1975). Commonly, two agents such as fluoride and tetracycline when ingested during amelogenesis have long been recognized as predisposing factors in intrinsic staining (Dean, Trendley Dean, and McKay 1939), (Bevelander, Rolle, and Cohlan 1961).

There are various invasive therapies that have been used to correct the discolouration of teeth such as crowning or the placement of veneers but whitening of teeth using a bleaching technique is a non invasive alternative which also conserves dental hard tissue (Attin et al. 2003). Vital teeth are whitened by nightguard vital bleaching technique (NGVB) utilizing carbamide peroxide gels which acts as the bleaching medium (Fasanaro 1992),

Haywood(Haywood 1992), EBSCOhost("EBSCOhost | 38506309 | Endodontic Therapy in a post Irradiated Child: Review of the Literature and Report of a Case" n.d.). On the other hand, whitening of root filled teeth is carried out by internal whitening treatment (walking bleach technique)(Weisman 1968), Geurtsen(Vernieks and Geurtsen 1986; Geurtsen and Vernieks 1986), Arens(Arens 1989)

The invasive intervention either partial restorations such laminate veneers or full-coverage dental restorations may be used to treat generalized intrinsic tooth discoloration for which bleaching may not be indicated or where the esthetic results of bleaching fail to meet the patient's expectations(Cutbirth 1992), Crispin(Crispin 1997), Walls(Walls, Steele, and Wassell 2002).

Previously numerous clinical trials (Jyothi et al. 2017), Duraisamy(Duraisamy et al. 2019), Ganapathy(D. Ganapathy 2016), systematic reviews (Ariga et al. 2018), Ganapathy(D. M. Ganapathy, Kannan, and Venugopalan 2017), Ganapathy(D. M. Ganapathy, Kannan, and Venugopalan 2017; Kannan and Venugopalan 2018), reviews (Selvan and Ganapathy 2016)6, Subasree(Subasree, Murthykumar, and Dhanraj 2016), Vijayalakshmi(Vijayalakshmi and Ganapathy 2016), in vitro studies (Jain, Ranganathan, and Ganapathy 2017), Ajay(Ajay et al. 2017), case reports (Ajay et al. 2017; Ashok et al. 2014), Ashok(Ashok et al. 2014; Venugopalan et al. 2014) and surveys (Ashok and Suvitha 2016), Ashok(Ashok and Suvitha 2016; Basha, Ganapathy, and Venugopalan 2018) have been conducted in Saveetha dental college over the past few years . Now, we are carrying out many such researches with our huge university database.

The aim of this study was to retrospectively assess the etiology, discoloured surfaces and outcomes of different techniques used for vital bleaching.

MATERIALS AND METHODS:

Study Setting:

The study was conducted with the approval of the Institutional Ethics Committee [SDC/SIHEC/2020/DIASDATA/0619-0320]. The study consisted of one reviewer, one assessor and one guide

Study Design:

The study was designed to include all dental patients of the ages 16-68 years who are undergoing treatment for bleaching of discoloured vital teeth. The patients who did not fall into this inclusion criteria were excluded.

Sampling Technique:

The study was based on a non probability consecutive sampling method. To minimise sampling bias, all case sheets of patients who are undergoing treatment bleaching of discoloured vital teeth were reviewed and included.The internal and external validity of the sample selected and all the samples are selected based on a simple random sample.

Data Collection and Tabulation:

Data Collection was done using the patient database with the timeframe work 01 June 2019 and 31 march 2020. About 31 case sheets were reviewed and those fitting under the inclusion criteria were included. Cross verification of data for errors and measures are taken to minimise sampling bias all data were included.The inclusion criteria was all the patients who are undergoing bleaching treatment for discoloured vital teeth. The exclusion criteria was patients with systemic disorders. Data was downloaded from DIAS and imported to Excel, Tabulation was done. The values were tabulated and analysed.

Statistical Analysis:

Descriptive statistics was used to evaluate the prevalence of etiology of discoloration, discoloured

teeth and outcomes of different techniques in vital tooth bleaching. Chi-Square test was performed and the p value was determined to evaluate the significance of the variables it was used to evaluate. The association between gender, age and etiology of discoloured vital teeth, between discoloured site and technique used and in between technique used and its outcome were evaluated and statistics were carried using SPSS Software version 23.0 by IBM. The results were obtained in the form of graphs and tables.

RESULTS & DISCUSSION:

Retrospective analysis of etiology, area concerned and various techniques used was done for patients who were opting for vital bleaching. A total of 31 sheets were analysed and data for which was extracted from the university database.

In the present study, fluorosis was the most prevalent etiology for vital tooth discolouration. As the people are concerned about their aesthetic smile, the discoloured vital teeth in the upper anterior area followed by both upper and lower anteriors were more approached for bleaching treatment. The conventional technique was most commonly used followed by power bleach. The prevalent etiology for the age group 16-25 yrs was Fluorosis followed by Stains. In the 26-45 yrs age group, Fluorosis followed by Aesthetics was prevalent. Whereas, in the 46+ yrs age group, Fluorosis and Aesthetics were equally prevalent.

In Females, Fluorosis followed by Aesthetics was maximum found. Whereas for Males, Fluorosis followed by Stains was prevalent. While observing the frequency distribution of techniques used in various areas of jaw, in upper anteriors, Conventional technique was most commonly used. For lower anteriors, Conventional followed by Power bleach was used. For both upper & lower anteriors and upper anteriors & premolars, conventional technique was most prevalent.

Power bleach had the most satisfactory results in 100%, but this cannot be made conclusive as the sample is very less for this group and might show positive results accordingly. Outcomes for conventional technique were more satisfactory than thermocatalytic.

Tooth discolouration history from patient record provides useful information regarding the etiology. In the management of patients with tooth discolouration, knowledge of mechanism of tooth discolouration is valuable in the decision-making process for treatment (Watts and Addy 2001).

The factors responsible for extrinsic tooth discolouration may be attributed to diet, oral hygiene, Habits, Medications, Occupation and environment and factors responsible for intrinsic tooth discolouration may be considered as 1) Pre-eruptive such as metabolic disorders, disturbance of tooth germ, genetic disorder, medication, environmental 2) Post-eruptive causes such as dental conditions, pulpal causes, dental materials

Treatment of tooth discoloration is based on identification of etiology and implementation of the required therapy. Scaling and polishing of teeth using prophylactic paste applied with a rotating rubber cup helps in removal of extrinsic stains. Discolouration of teeth caused by dental caries or dental materials require the removal of caries/restorative materials followed by proper restoration of the tooth.

Dental restorations such as crowns and laminate veneers are mostly used to treat generalized teeth discoloration where bleaching therapy is not indicated or when the outcome of bleaching therapy fails to meet the patient's expectations about esthetics. The various situational factors such as age and treatment factors such as techniques can modify the outcome of the bleaching procedure.

Bleaching is considered safe for the dental pulp. Fugaro et al. evaluated the histological changes in

the dental pulp after night guard vital bleaching with a 10% carbamide peroxide gel. The findings indicated that the mild histological changes sometimes observed after bleaching tend to resolve within two weeks after treatment, and they have no effect on the overall health of the pulp tissue (Fugaro et al. 2004).

In the present study, It was found that fluorosis contributed to about 74.2% of the prevalent etiology. Also, fluorosis was the most common etiology amongst both males and females followed by stains and aesthetic reasons. These results highlight the exposure to higher concentrations of fluoride in our drinking water and other sources & should be reduced which are the cause of endemic dental mottling. Fluorosis is a common disorder in Saudi Arabia (Akpata, Fakiha, and Khan 1997), especially in rural areas, where drinking water contains high levels of fluoride.

The upper anterior (UA) area was almost always being treated with bleaching, thereby, explaining aesthetic reasons followed by bleaching in both upper and lower anteriors. It was observed that conventional technique was most commonly used and had the highest levels of satisfactory results amongst patients.

CONCLUSION:

Within the limitations of the study, we conclude that fluorosis was the most prevalent etiology for vital tooth discolouration. Discoloration of the upper anterior tooth was reported more often. The conventional technique was most commonly used followed by power bleach. Outcomes for conventional technique were more satisfactory than thermocatalytic technique for the management of vital tooth discoloration.

ACKNOWLEDGEMENT:

We would like to thank all the participants who took part in the study. We also thank Saveetha dental

college and hospitals for their constant help and support.

AUTHOR CONTRIBUTION:

First author (Dr. Madhura Deshmukh) performed the analysis and interpretation and wrote the manuscript. Second author (Dr. Nabeel Ahmed) contributed to conception, data design, analysis, interpretation and critically revised the manuscript. Both the authors have discussed results and revised the manuscript.

CONFLICT OF INTEREST:

The authors declare no conflict of interest, financial or otherwise.

REFERENCES:

1. Ahmed, Hussain Gadelkarim. 2017. "Knowledge and Practice of Saudi Civilians towards Management of Dental Trauma and Avulsed Tooth." *Journal of Dental Health, Oral Disorders & Therapy*. <https://doi.org/10.15406/jdhodt.2017.06.00183>.
2. Ajay, R., K. Suma, Seyedasharaf Ali, Jambaisampath Kumar Sivakumar, V. Rakshagan, V. Devaki, and K. Divya. 2017. "Effect of Surface Modifications on the Retention of Cement-Retained Implant Crowns under Fatigue Loads: An In Vitro Study." *Journal of Pharmacy And Bioallied Sciences*. https://doi.org/10.4103/jpbs.jpbs_146_17.
3. Akpata, E. S., Z. Fakiha, and N. Khan. 1997. "Dental Fluorosis in 12-15-Year-Old Rural Children Exposed to Fluorides from Well Drinking Water in the Hail Region of Saudi Arabia." *Community Dentistry and Oral Epidemiology* 25 (4): 324–27.

4. Arens, D. 1989. "The Role of Bleaching in Esthetics." *Dental Clinics of North America* 33 (2): 319–36.
5. Ariga, Padma, Deepak Nallaswamy, Ashish R. Jain, and Dhanraj M. Ganapathy. 2018. "Determination of Correlation of Width of Maxillary Anterior Teeth Using Extraoral and Intraoral Factors in Indian Population: A Systematic Review." *World Journal of Dentistry*. <https://doi.org/10.5005/jp-journals-10015-1509>.
6. Ashok, V., Deepak Nallaswamy, S. Benazir Begum, and Thiyaneswaran Nesappan. 2014. "Lip Bumper Prosthesis for an Acromegaly Patient: A Clinical Report." *The Journal of Indian Prosthodontic Society*. <https://doi.org/10.1007/s13191-013-0339-6>.
7. Ashok, V., and S. Suvitha. 2016. "Awareness of All Ceramic Restoration in Rural Population." *Research Journal of Pharmacy and Technology*. <https://doi.org/10.5958/0974-360x.2016.00340.1>.
8. Attin, T., F. Paque, F. Ajam, and A. M. Lennon. 2003. "Review of the Current Status of Tooth Whitening with the Walking Bleach Technique." *International Endodontic Journal*. <https://doi.org/10.1046/j.1365-2591.2003.00667.x>.
9. Basha, Farhat Yaasmeen Sadique, Dhanraj Ganapathy, and Suresh Venugopalan. 2018. "Oral Hygiene Status among Pregnant Women." *Research Journal of Pharmacy and Technology*. <https://doi.org/10.5958/0974-360x.2018.00569.3>.
10. Bevelander, Gerrit, Gloria K. Rolle, and Sidney Q. Cohlan. 1961. "The Effect of the Administration of Tetracycline on the Development of Teeth." *Journal of Dental Research* 40 (5): 1020–24.
11. Crispin, B. J. 1997. "The Full Veneer as an Alternative to the Full Crown." *Current Opinion in Cosmetic Dentistry* 4: 6–10.
12. Cutbirth, Steven T. 1992. "Indirect Porcelain Veneer Technique for Restoring Intrinsically Stained Teeth." *Journal of Esthetic and Restorative Dentistry*. <https://doi.org/10.1111/j.1708-8240.1992.tb00695.x>.
13. Dean, H. Trendley, H. Trendley Dean, and Frederick S. McKay. 1939. "Production of Mottled Enamel Halted by a Change in Common Water Supply." *American Journal of Public Health and the Nations Health*. <https://doi.org/10.2105/ajph.29.6.590>.
14. Duraisamy, Revathi, Chitra Shankar Krishnan, Hariharan Ramasubramanian, Jayakrishnakumar Sampathkumar, Saravanakumar Mariappan, and Azhagarasan Navarasampatti Sivaprakasam. 2019. "Compatibility of Nonoriginal Abutments With Implants: Evaluation of Microgap at the Implant-Abutment Interface, With Original and Nonoriginal Abutments." *Implant Dentistry* 28 (3): 289–95.
15. "EBSCOhost | 38506309 | Endodontic Therapy in a Postirradiated Child: Review of the Literature and Report of a Case." n.d. Accessed June 13, 2020. <http://search.ebscohost.com/login.aspx?direct=true&profile=ehost&scope=site&authtype=crawler&jrnl=00336572&AN=38506309&h=v%2FZyOU2wd8uQyG4zh85TEjebjcmSJzWdshGj55ju7WfihltZQNNbVPSypCGKTegjgFb%2BwwMCTDkCOQV3fED8uA%3D%3D&crl=c>.

16. Fasanaro, T. S. 1992. "Bleaching Teeth: History, Chemicals, and Methods Used for Common Tooth Discolorations." *Journal of Esthetic Dentistry* 4 (3): 71–78.
17. Fugaro, Jessica O., Inger Nordahl, Orlando J. Fugaro, Bruce A. Matis, and Ivar A. Mjör. 2004. "Pulp Reaction to Vital Bleaching." *Operative Dentistry* 29 (4): 363–68.
18. Ganapathy, Dhanraj. 2016. "Effect of Resin Bonded Luting Agents Influencing Marginal Discrepancy in All Ceramic Complete Veneer Crowns." *JOURNAL OF CLINICAL AND DIAGNOSTIC RESEARCH*. <https://doi.org/10.7860/jcdr/2016/21447.9028>.
19. Ganapathy, Dhanraj M., Abinaya Kannan, and Suresh Venugopalan. 2017. "Effect of Coated Surfaces Influencing Screw Loosening in Implants: A Systematic Review and Meta-Analysis." *World Journal of Dentistry*. <https://doi.org/10.5005/jp-journals-10015-1493>.
20. Geurtsen, W., and A. A. Vernieks. 1986. "[Bleaching stained vital teeth]." *ZWR* 95 (1): 54–55.
21. Hattab, Faiez N., Muawia A. Qudeimat, and Hala S. Al-Rimawi. 1999. "Dental Discoloration: An Overview." *Journal of Esthetic and Restorative Dentistry*. <https://doi.org/10.1111/j.1708-8240.1999.tb00413.x>.
22. Haywood, Van Benjamine. 1992. "History, Safety, and Effectiveness of Current Bleaching Techniques and Applications of the Nightguard Vital Bleaching Technique." <https://pdfs.semanticscholar.org/8229/613cb181c5665113d7ce62f46c4f2aee0b35.pdf>
23. Jain, Ashishr, Hemalatha Ranganathan, and Dhanrajm Ganapathy. 2017. "Cervical and Incisal Marginal Discrepancy in Ceramic Laminate Veneering Materials: A SEM Analysis." *Contemporary Clinical Dentistry*. https://doi.org/10.4103/ccd.ccd_156_17.
24. Jyothi, S., Pon Kirubha Robin, Dhanraj Ganapathy, and Anandiselvaraj. 2017. "Periodontal Health Status of Three Different Groups Wearing Temporary Partial Denture." *Research Journal of Pharmacy and Technology*. <https://doi.org/10.5958/0974-360x.2017.00795.8>.
25. Kannan, Abinaya, and Suresh Venugopalan. 2018. "A Systematic Review on the Effect of Use of Impregnated Retraction Cords on Gingiva." *Research Journal of Pharmacy and Technology*. <https://doi.org/10.5958/0974-360x.2018.00393.1>.
26. Selvan, Subashree Rathi, and Dhanraj Ganapathy. 2016. "Efficacy of Fifth Generation Cephalosporins against Methicillin-Resistant Staphylococcus Aureus-A Review." *Research Journal of Pharmacy and Technology*. <https://doi.org/10.5958/0974-360x.2016.00369.3>.
27. Subasree, S., Karthikeyan Murthykumar, and Dhanraj. 2016. "Effect of Aloe Vera in Oral Health-A Review." *Research Journal of Pharmacy and Technology*. <https://doi.org/10.5958/0974-360x.2016.00116.5>.
28. Sulieman, M. 2005. "An Overview of Tooth Discoloration: Extrinsic, Intrinsic and Internalized Stains." *Dental Update*. <https://doi.org/10.12968/denu.2005.32.8.463>.

29. Venugopalan, S., P. Ariga, P. Aggarwal, and A. Viswanath. 2014. "Magnetically Retained Silicone Facial Prosthesis." *Nigerian Journal of Clinical Practice* 17 (2): 260–64.
30. Vernieks, A. A., and W. Geurtsen. 1986. "[Bleaching of stained non-vital teeth]." *ZWR* 95 (2): 130–34.
31. Vijayalakshmi, B., and Dhanraj Ganapathy. 2016. "Medical Management of Cellulitis." *Research Journal of Pharmacy and Technology*. <https://doi.org/10.5958/0974-360x.2016.00422.4>.
32. Vogel, R. I. 1975. "Intrinsic and Extrinsic Discoloration of the Dentition (a Literature Review)." *Journal of Oral Medicine* 30 (4): 99–104.
33. Walls, A. W. G., J. G. Steele, and R. W. Wassell. 2002. "Crowns and Other Extra-Coronal Restorations: Porcelain Laminate Veneers." *British Dental Journal*. <https://doi.org/10.1038/sj.bdj.4801489>.
34. Watts, A., and M. Addy. 2001. "Tooth Discolouration and Staining: A Review of the Literature." *British Dental Journal* 190 (6): 309–16.
35. Weisman, H. N. 1968. "Bleaching Nonvital Teeth." *Dental Survey* 44 (2): 52–53.

TABLES AND FIGURES:

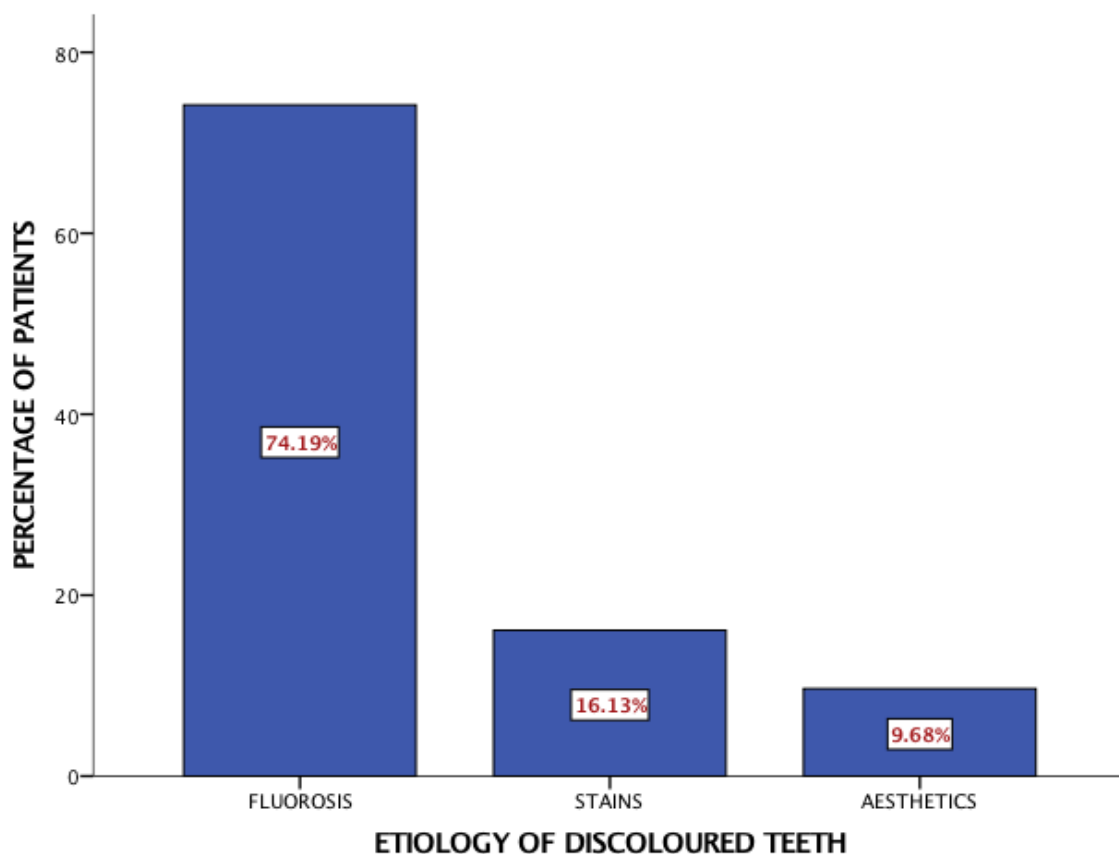


Figure 1: Bar graph depicting the distribution of various etiologies of tooth discolouration prior to bleaching of vital teeth. X axis represents different etiologies of discoloured vital teeth, Y axis represents the percentage of the population. It shows that Fluorosis is the most prevalent etiology in about 74.19%, followed by Stains in 16.13% and least Aesthetic reasons in the 9.68% population.

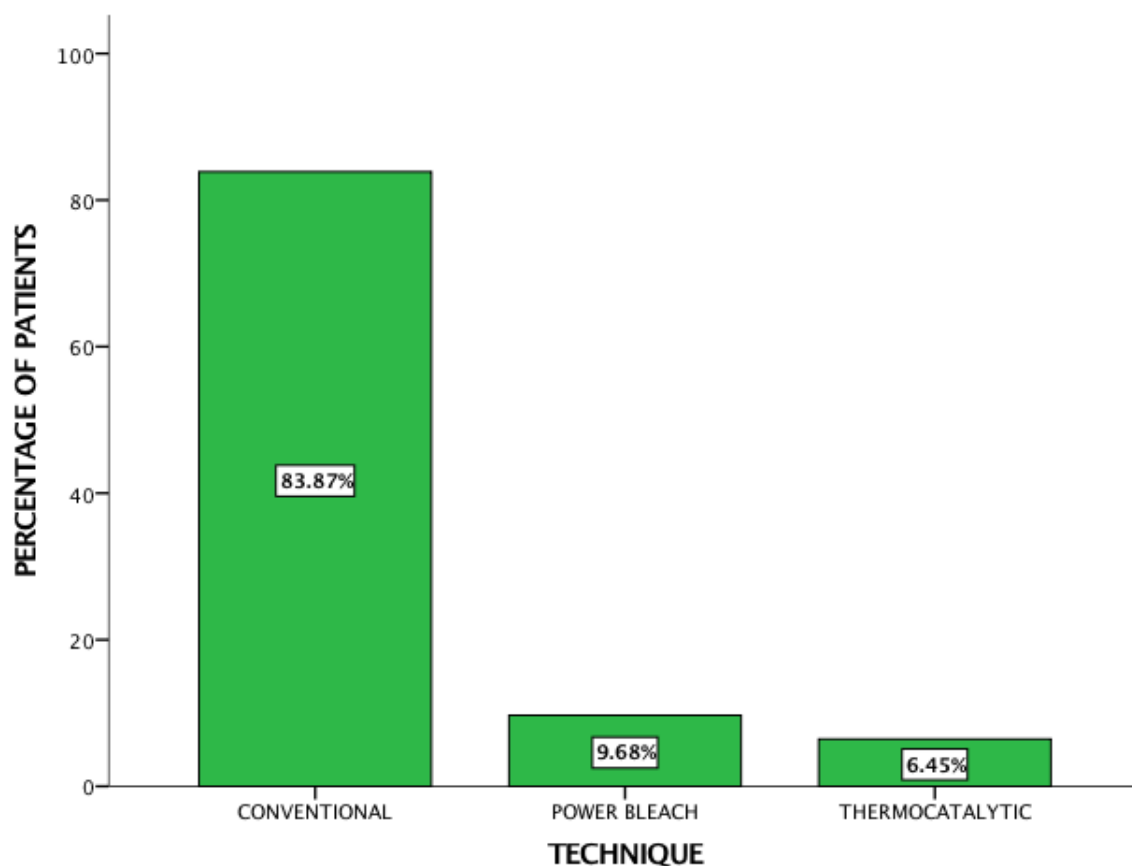


Figure 2: Bar graph depicts distribution of various techniques used for tooth discolouration prior to bleaching of vital teeth. X axis represents different techniques used in bleaching and the Y axis represents the percentage of population. It shows that Conventional is the most preferred technique in about 83.87%, followed by Power Bleach in 9.68% and least Thermocatalytic in 6.45% population.

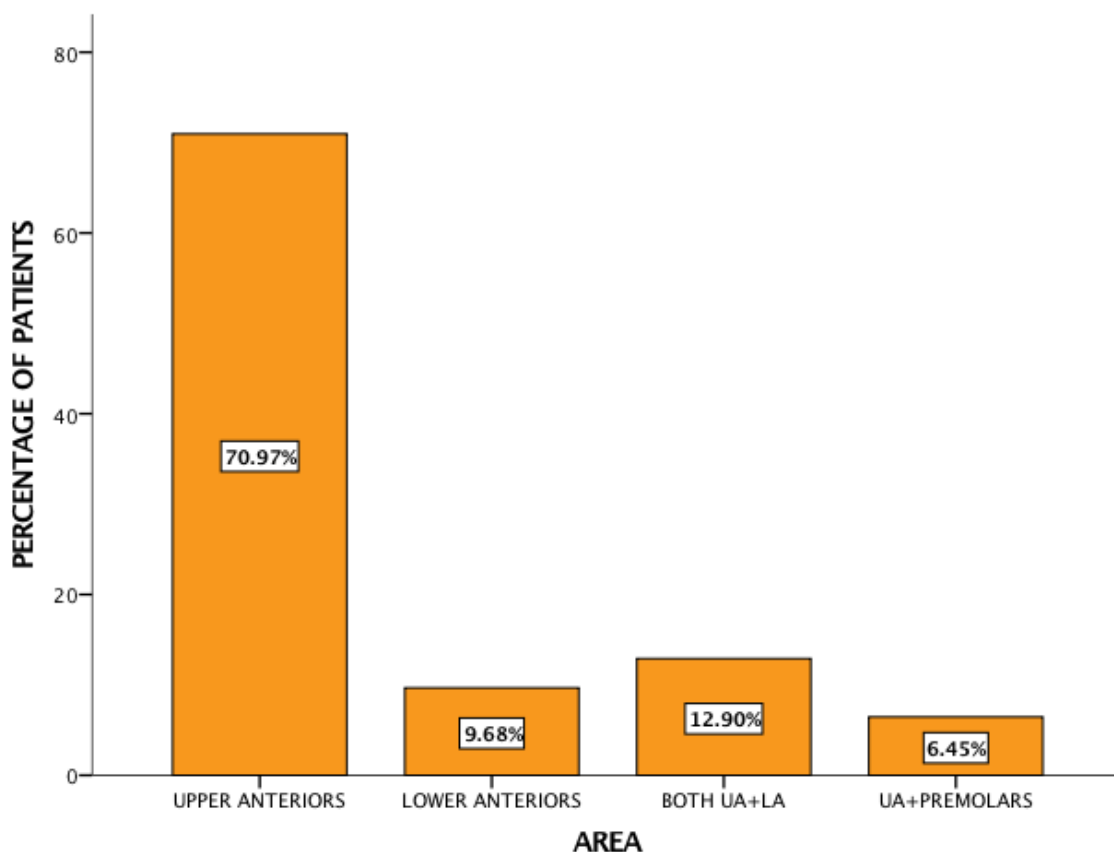


Figure 3: Bar graph depicting the distribution of various sites of tooth discolouration prior to bleaching of vital teeth. X axis represents different areas of discoloured teeth and Y axis represents the percentage of the population. It shows that Upper anteriors presented with discoloration in about 70.97%, followed by both upper and lower anteriors in 12.90%, then lower anteriors in 9.68% and least upper anteriors with premolars in 6.45% population.

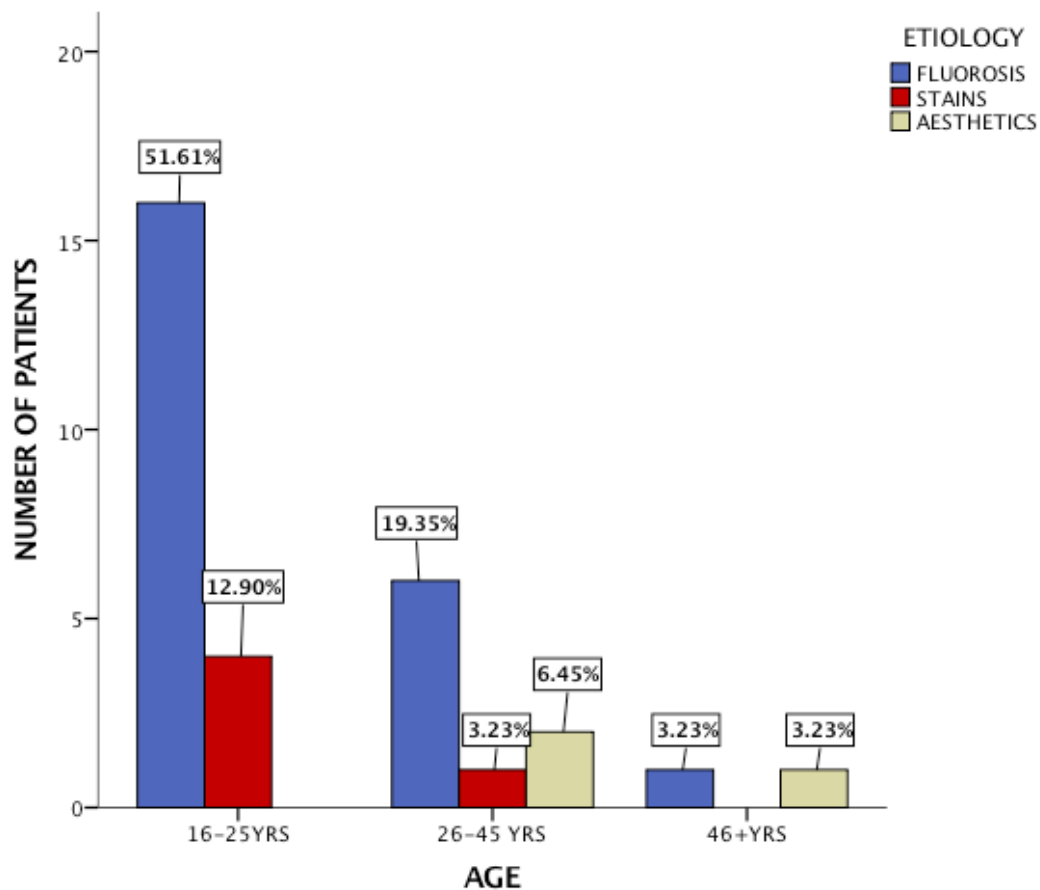


Figure 4: Bar graph depicts the distribution of etiologies of discoloured vital teeth prior to bleaching and its association with age. X axis represents age groups, Y axis represents number of population. It shows in both 16-25 yrs and 26-45 yrs, fluorosis was the most prevalent etiology. In 46+yrs, both fluorosis and stains were equally prevalent. Chi Square test [(Pearson's Chi-square value: 7.726, df : 4 , p-value: 0.102 ($p > 0.05$))] was done showing no association of initial shade and age making them statistically not significant.

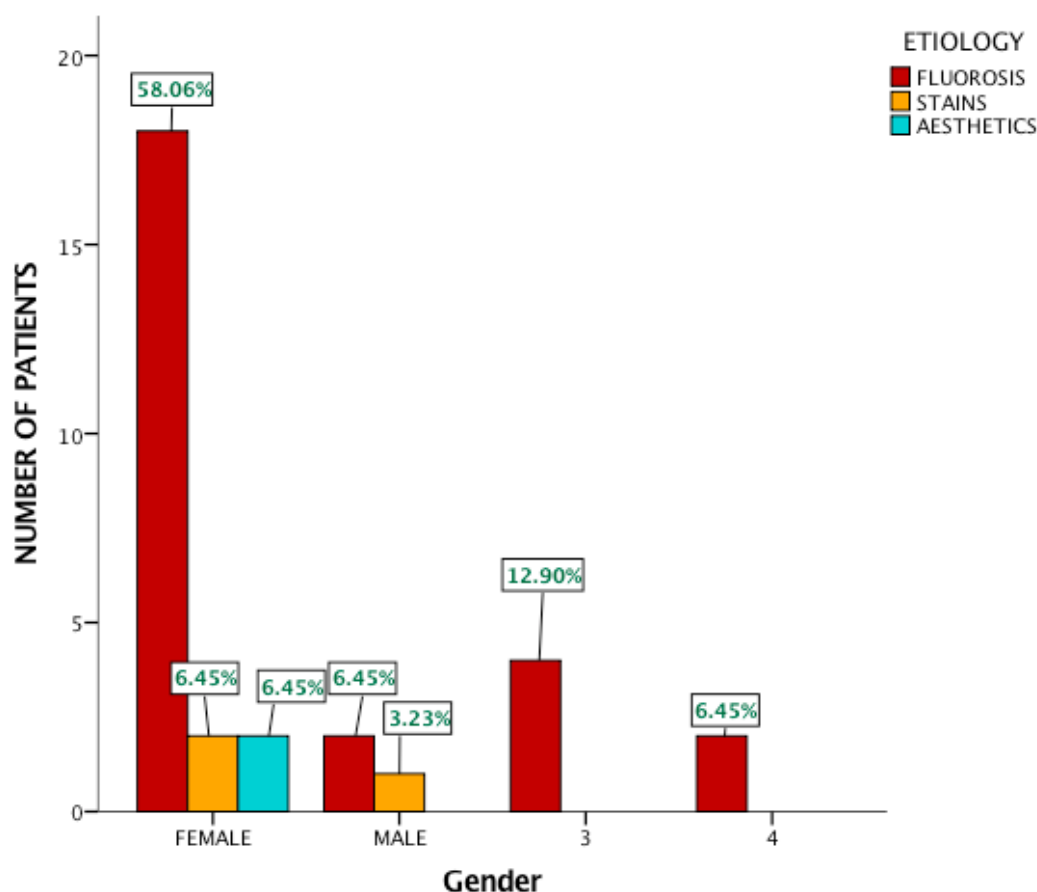


Figure 5: Bar graph depicts the distribution of etiologies of discoloured vital teeth prior to bleaching and its association with gender. X axis represents gender, Y axis represents number of population. It shows that in both Males and Females, Fluorosis is the most prevalent etiology. Chi Square test [(Pearson's Chi-square value: 1.855, df: 2 , p-value: 0.395 ($p > 0.05$))] was done showing no association of initial shade and gender making them statistically not significant.

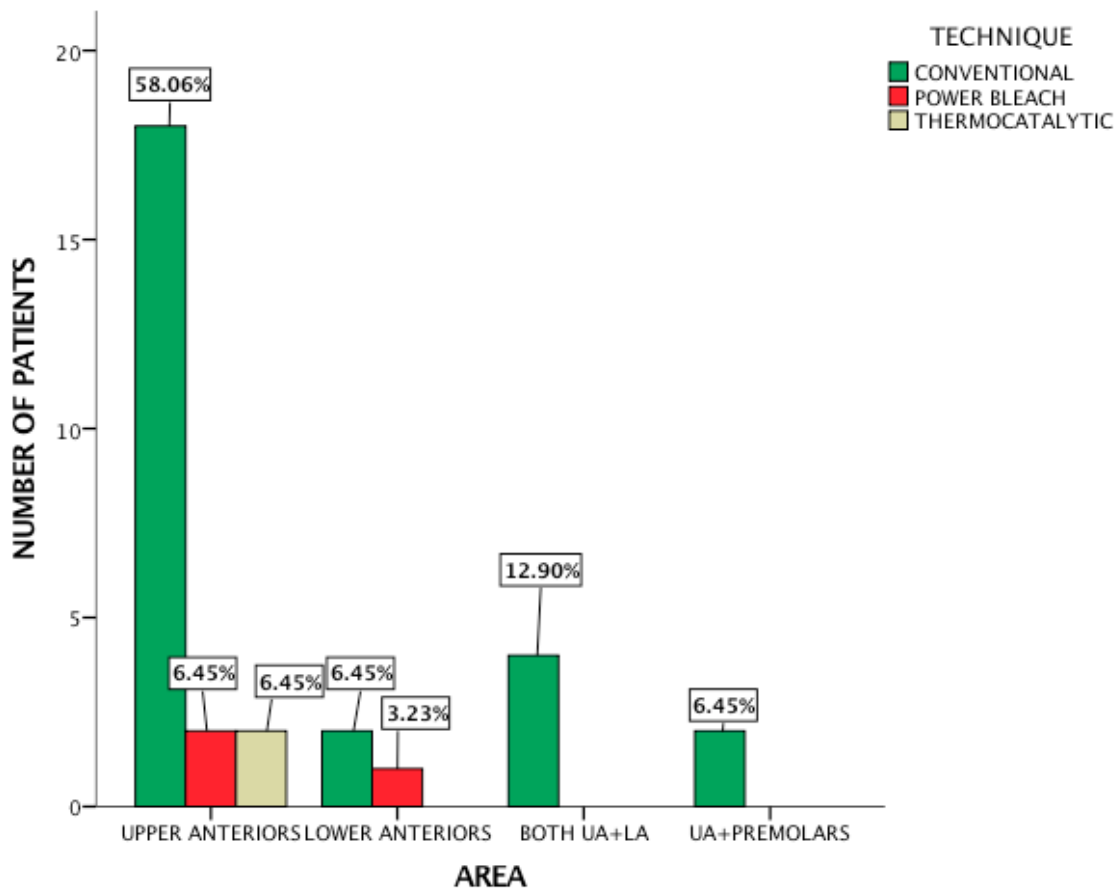


Figure 6: Bar graph depicts techniques used for vital teeth bleaching and its association with site. X axis represents sites, Y axis represents number of population. It shows that in all sites, conventional technique is the most preferred technique. Chi Square test [(Pearson's Chi-square value: 3.444, df: 6, p-value: 0.751($p > 0.05$))] was done showing no association of initial shade and site making them statistically not significant.

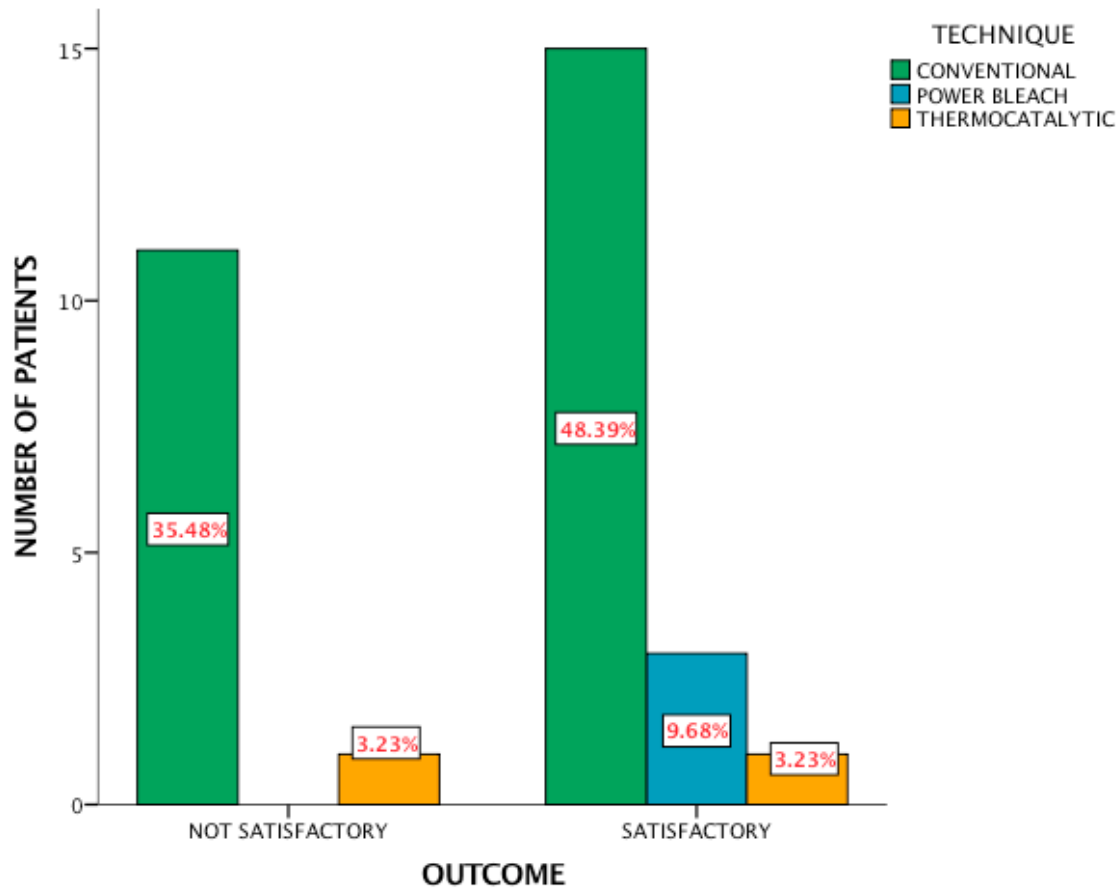


Figure 7: Bar graph depicts the techniques used for vital teeth bleaching and its association with outcome. X axis represents outcome, Y axis represents number of population. It shows that the outcome for both Conventional and Power bleach technique was satisfactory. Chi Square test [(Pearson's Chi-square value: 2.144, df: 2, p-value: 0.342($p > 0.05$))] was done showing no association of technique and outcome making them statistically not significant.