

# Aesthetic Management of Anterior Discolouration of Teeth - An Institution based Retrospective Study

Running Title: Aesthetic management of anterior discolouration of teeth

**J.ChandraPooja**

*Saveetha Dental College and Hospitals  
Saveetha Institute of Medical and Technical Sciences  
Saveetha University  
Chennai, India  
Email: 151501060.sdc@saveetha.com*

**Dr. Padma Ariga**

*Professor  
Department Of Prosthodontics  
Saveetha Dental College and Hospitals  
Saveetha Institute of Medical and Technical Sciences  
Saveetha University  
Chennai, India  
Email: padma@saveetha.com*

**Dr.Ganesh Jeevanandan**

*Reader  
Department of Pedodontics  
Saveetha Dental College and Hospitals  
Saveetha Institute of Medical and Technical Sciences  
Saveetha University  
Chennai, India  
Email: ganesh.sdc@saveetha.com*

## **CORRESPONDING AUTHOR**

**Dr. Padma Ariga**

*Professor  
Department Of Prosthodontics  
Saveetha Dental College and Hospitals  
Saveetha Institute of Medical and Technical Sciences  
Saveetha University  
162, PH Road, chennai 600077  
Tamilnadu, India  
Email: padma@saveetha.com*

**Article Info****Volume 83****Page Number: 2625 - 2635****Publication Issue:****July-August 2020****Abstract:**

Dental aesthetics has considerable impact on a person's confidence in a society. The darkening of the anterior teeth causes concern for adolescents due to the compromised physical appearance. The aim of the study was to assess different aesthetic treatments preferred by patients for anterior teeth discolouration in a university hospital setting. A retrospective study was carried out using case records of 76 patients who reported to the Department of Aesthetic dentistry from June 2019 to March 2020. The various methods preferred for treatment discolouration of anterior teeth were observed from the digital records and tabulated on a spreadsheet. The collected data were analysed by computer software SPSS version 21 using Chi square test indicating the level of significance. The common reasons for discolouration were fluorosis (22.4%), tobacco stains (10.5%), post root canal treatment (60.5%), enamel hypoplasia (1.3%), traumatic injury (2.6%) and unknown reasons (2.6%) and the most common reason for discoloration was post root canal treatment (60.5%) and the treatment for management of discolouration were directing veneering (7.9%), indirect veneering (5.3%), vital bleaching (25%) and non vital bleaching (61.8%) and the most preferred treatment was non vital bleaching (61.8%). Among the age groups 18-66 male patients below the age group of 30 desired treatment for their anterior tooth discolouration compared to the other age groups. The reason for discolouration had significant association with age (p value-0.00) and no significant association with gender (p value-0.82). Regarding the treatment preferred for discolouration age had no significant association (p value-0.94) while gender had significance (p value-0.02).

**Article History****Article Received: 06 June 2020****Revised: 29 June 2020****Accepted: 14 July 2020****Publication: 25 July 2020****Keywords:** Anterior discolouration; enamel hypoplasia; fluorosis; dental aesthetics; non vital bleaching; tobacco stains, trauma to anterior teeth.**INTRODUCTION**

The appearance of the dentition is of concern to a large number of people seeking dental treatment and the colour of the teeth is of particular cosmetic importance (Watts and Addy, 2001). It is also known that the satisfaction degree toward the aesthetics of the mouth is related to the self-consciousness of an individual (Klages, Bruckner and Zentner, 2004) (Ashok *et al.*, 2014). Therefore, any defect in the anterior teeth may impair the outward appearance of that person. How this impairment affects the psychology of that human being is worth a discussion and detailed analysis (Gupta, Sadana and Rai, 2019) (Venugopalan *et al.*, 2014).

Discolouration of anterior teeth is a complex aesthetic problem in restorative dentistry (Lui, 1987). Defects in the anterior teeth, which affect the aesthetic appearance of an individual, may be the result of traumatic injuries, pulpal pathologies, dental caries,

developmental disturbances, fluorosis, opacities, etc. (Holan, Rahme and Ram, 2009).

Studies conclude that the majority of the adolescents who have anterior discolouration did not like the condition. They wanted the discolouration to be removed persistently (Ibiyemi and Taiwo, 2011). There is a need to intensify child immunization efforts and destruction or removal of all pathogenic organisms, or organisms capable of giving rise to infection- disinfection in the community as well as health education since in recent decades, microbial resistance has reached to an incredibly alarming levels, leading to the development of more potent antimicrobial agents (Selvan and Ganapathy, 2016). The establishment of school meals in primary and secondary schools for improving nutrition and preventing tooth discolouration associated with poor nutrition (Koleoso, Shaba and Isiekwe, 2004) and periodontal status with the increasing incidence of periodontal diseases and development of antibiotic

resistance, there is a global need for alternative treatment modalities that is safe, effective and economical (Subasree, Murthykumar and Dhanraj, 2016) (Vijayalakshmi and Ganapathy, 2016) and is identified by initial periodontal assessment with plaque score (PLS), bleeding on probing (BOP), probing pocket depth (PPD), loss of attachment (LOA), furcation and mobility (Jyothi *et al.*, 2017) (Basha, Ganapathy and Venugopalan, 2018).

Tooth discoloration is related to many clinical and esthetical challenges which can affect a person's self image and self confidence where most people place tooth colour high. Lack of awareness about management of discolouration may require Root Canal Treatment, veneering and replacement followed by extraction which becomes a psychological and financial burden on the patient (Duraishamy *et al.*, 2019) (Ganapathy, Kannan and Venugopalan, 2017).

The aesthetic treatment for anterior tooth discolouration includes vital and non vital bleaching and direct or indirect veneering with composites and ceramic depending upon the age, gender, literacy and socioeconomic status. Vital tooth bleaching can be performed externally in vital teeth, using at-home or in-office techniques, or both techniques in combination (Demarco, Meireles and Masotti, 2009). Nonvital bleaching for a root-filled tooth is carried out intracoronary or using a combination of external and internal procedures. Several products and different techniques are available for tooth bleaching, with most variations relating to concentration and type of peroxide releasing agents (Joiner, 2006). Aesthetic veneers demonstrate excellent clinical performance and, as materials and techniques have evolved, veneers have become one of the most predictable, most aesthetic, and least invasive modalities of treatment (Radz, 2011) (Ganapathy *et al.*, 2016) (Ashok and Suvitha, 2016) (Kannan and Venugopalan, 2018). The aim of the study was to evaluate different aesthetic approaches preferred by

patients in a teaching institution for discolouration of anterior teeth.

## MATERIALS AND METHOD

### Study design and Study setting

The present study was conducted in a hospital in Chennai to evaluate the reasons for anterior discolouration and treatments opted for management of discolouration, from June 2019 to March 2020. The retrospective study was carried out with the help of case records of 76 patients who reported to the dental hospital for treatment. Since it is a retrospective study, carried out using patient case records, no informed consent was required from the patient. Ethical clearance to conduct this study was obtained from the Scientific Review Board of the hospital. All retrospective studies arising from the Data set between 01 June 2019 and 31 March 2020 will be covered by the following ethical approval number. SDC/SIHEC/2020/DIASDATA/0619-0320.

### Sampling

The type of study was Retrospective. The data of 76 patients were reviewed and then extracted. Only relevant data was included to minimize bias. Non probability sampling method was carried out. Cross verification of data for errors was done with the help of clinical photographs. The study contained regional data generalised to the South Indian population.

### Data Collection

A single calibrated examiner evaluated the case records of the 76 patients from June 2019 to March 2020. The reasons for anterior teeth discolouration and aesthetic management treatments opted for anterior teeth discolouration were reviewed. The following data were retrieved from the dental records: patient age, gender, management and reason for discolouration.

### Statistical Analysis

The collected data was validated, tabulated and analysed with Statistical Package for Social Sciences

for Windows, version 20.0 (SPSS Inc., Chicago, IL, USA) and results were obtained. Categorical variables were expressed in frequency and percentage; and continuous variables in mean and standard deviation. Chi-square test was used to test associations between categorical variables. Chi Square tests were carried out using demographic data like age and gender as independent variables and reasons for discolouration and treatment opted as the dependent variable. P value < 0.05 was considered statistically significant.

mean age of 0.21 years were included in the present study. Chi-square test was done between the treatment opted with age and gender, and reason for discolouration with age and gender.

The reasons for discolouration below the age group of below 30 years were fluorosis (21.05%), tobacco stains (9.21%), discolouration post rct (46.05%), traumatic injury(1.32%) and unknown reason(1.32%). Between the age of 31-60 years the reasons for discolouration were fluorosis(1.32%), tobacco stains(1.32%), discolouration post rct(14.47%) and aesthetic reasons(1.32%). Above the age of 60 years the reason for discolouration was enamel hypoplasia(1.32%). Figure 1 and table 1

## RESULTS AND DISCUSSION

A total of 76 patients who opted for treatment of anterior discolouration from 18 to 60 years with a

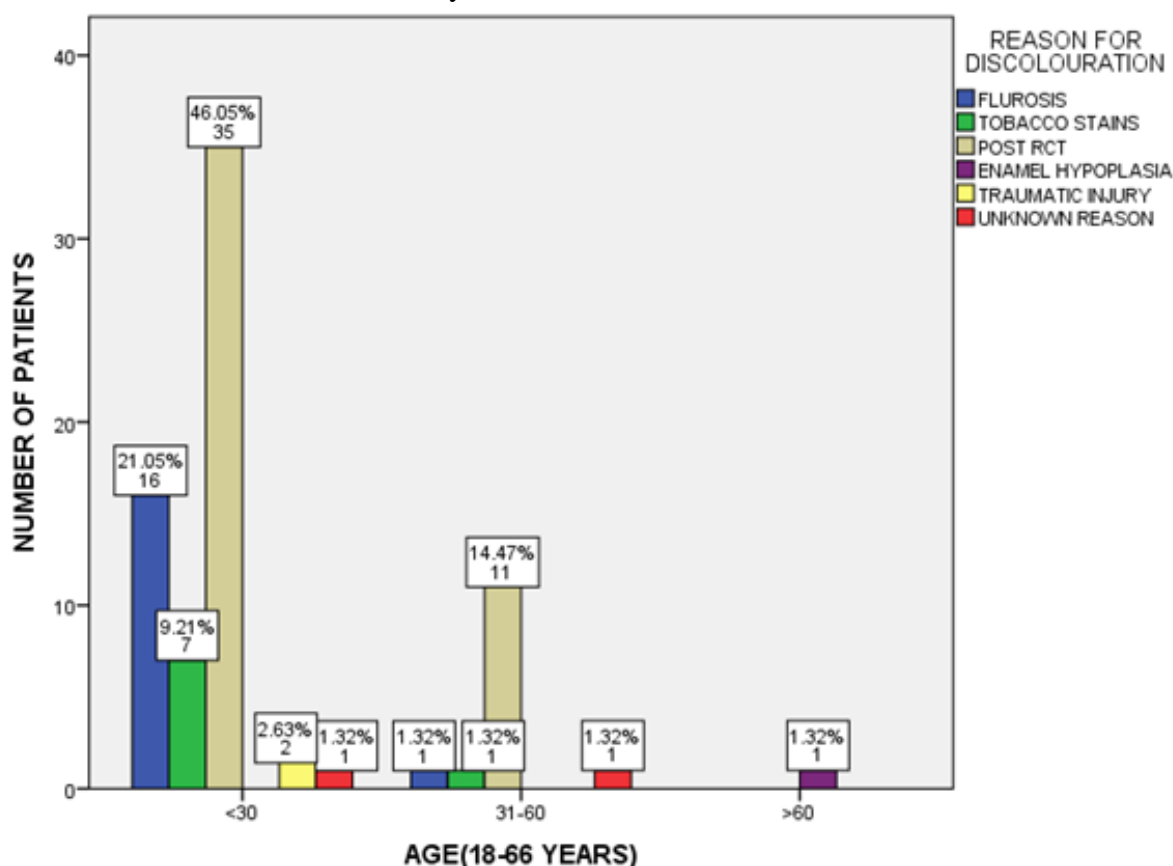


Figure 1 : Bar chart represents the correlation of age and reason for anterior discolouration of teeth. X-axis

represents the age and Y-axis represents the number of patients. Blue colour shows fluorosis, green colour shows tobacco stains, beige shows post rct, purple shows enamel hypoplasia, yellow colour shows traumatic injury and red colour shows unknown reasons for discolouration. Post root canal treatment was the most common reason for discolouration in both below 30 years(46.05%) and between 31-60 years(14.47%). This relation was analysed with Chi-square test and it was significant( Pearson's chi square value 80.678, df-10, p value = 0.001) .

shows correlation of age and reason for discolouration.

The study results were similar to result of Watts and Bosch's study which stated that extrinsic factors like smoking, stains, and intrinsic factors such as tetracycline staining, teeth vitality, age, and congenital defects are known to affect the tooth color and concluded that there was significant correlation between age and reason for discolouration (Watts and Addy, 2001) (ten Bosch and Coops, 1995).It is seen that the most common reason for discolouration was the discoloration occurring after root canal treatment which can be explained by increased number of trauma cases nowadays and fluorosis which is due to the high concentration of fluoride in the groundwater which is used for drinking purposes in India according to kabilan et al(Kabilan *et al.*, 2018). A research by Solheim has revealed the

association of increased age with darker, yellow teeth(Solheim, 1988).The factors attributed to this process are increased secondary dentin thickness, decreasing enamel thickness, occlusal wear, and pigment deposition within dentin structure.

Our study shows significant association between age and reason for discolouration according to Pearson's chi square test [ P value - 0.00].

Regarding gender and reason for discolouration, in male patients the reasons for discolouration were fluorosis (18.42%), tobacco stains (7.89%), discolouration post rct(44.74%), enamel hypoplasia (1.32%), traumatic injuries (1.32%) and unknown reason(1.32%). In female patients the reasons were fluorosis (2.63%), tobacco stains (2.63%), discolouration post rct (15.79%) ,traumatic injuries (1.32%) and aesthetic reasons (1.32).Figure 2 and table 2

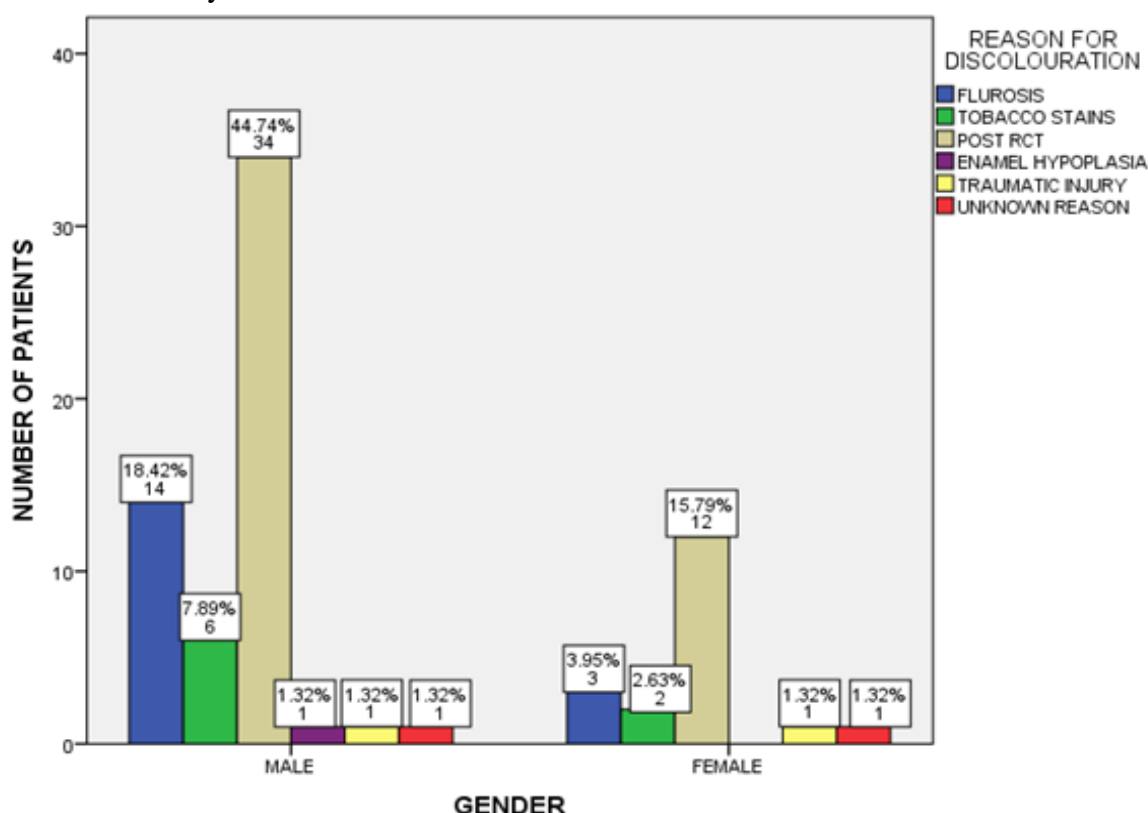


Figure 2 : Bar chart represents the correlation of gender and reason of anterior discolouration of teeth. X-axis represents the gender and Y-axis represents the number of patients. Blue colour shows fluorosis, green colour shows tobacco stains, beige shows post rct, purple shows enamel hypoplasia, yellow colour shows traumatic injury and red colour shows unknown reasons for discolouration. Post root canal treatment was the most common reason for discolouration in both male(44.47%) and female(15.79%) patients. This relation was analysed with Chi-square test and it was not significant(Pearson's chi square value 2.186, df-5, P value = 0.823 ).

shows association of gender and reason for discolouration.

The study had dissimilar results to that of Goodkind and Schwabacher's study which reported that women on an average have lighter, less reddish, and more yellow teeth and showed correlation between gender and reasons for discolouration (Goodkind and Schwabacher, 1987). A study by Demirel and Tuncdemir concluded gender had significant correlation with reason for discolouration that women had lighter and less yellow central incisors than men which differs due to habits, different population groups and incidence of trauma(Demirel and Tuncdemir, 2019).

Our study shows no significant association between gender and reason for discolouration according to Pearson's chi square test [ P value - 0.82].

Some of the commonly preferred treatments for anterior discoloration were vital and non-vital bleaching and direct and indirect veneering. All-ceramic laminate veneer restorations have rendered excellent service in restoring discolored teeth(Ranganathan, Ganapathy and Jain, 2017).All

ceramic veneering has some disadvantages like discrepancy in marginal fit facilitates, salivary infiltration and microleakage resulting in dissolution of the luting cement; thus, increasing the susceptibility to caries, eventually leading to pulpal damage(Ganapathy *et al.*, 2016) and masticatory forces cause fatigue to the dental luting agents, adversely affecting the retention of these cement-retained crowns(Ajay *et al.*, 2017).Gingival margins exposure during tooth preparation before impression making is one of the most technique-sensitive procedures for the dentist to perform(Jain and Nallaswamy, 2018).

Treatment options preferred for management of discolouration below the age group of 30 years, were direct veneering(5.26%), non-vital bleaching(50%), vital bleaching(21.05%) and indirect veneering(3.95%). Between the age group of 31-60 years, treatments opted were direct veneering (2.63%), non-vital bleaching(10.53%), vital bleaching(3.95%) and indirect veneering(1.32%). Above the age of 60 years the treatment opted was indirect veneering(1.32%). Figure 3 and table 3



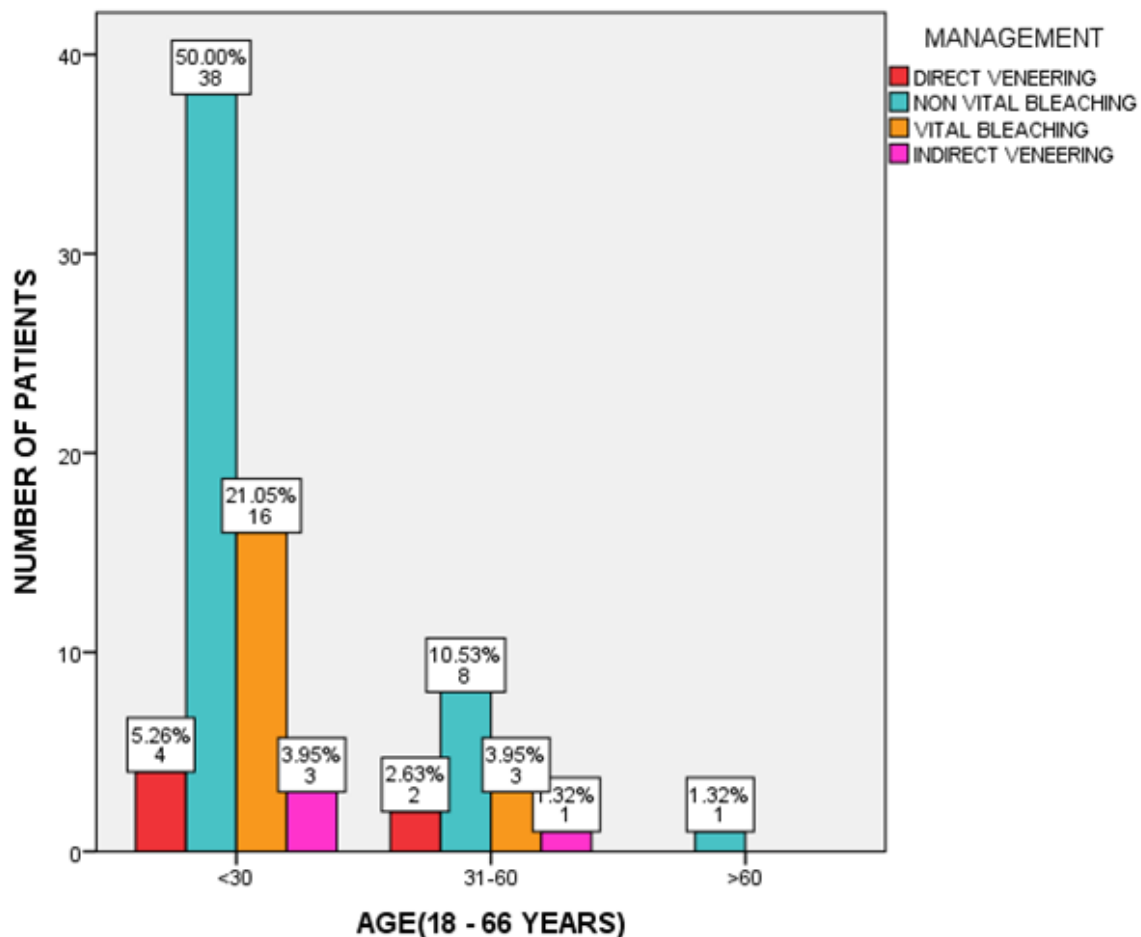


Figure 3 : Bar chart represents the association of age and management of anterior discolouration of teeth. X-axis represents the age and Y-axis represents the number of patients. Red colour shows direct veneering, blue colour shows non vital bleaching, orange color shows vital bleaching and pink colour shows indirect veneering. Non vital bleaching was the most common treatment opted in all the age groups(50%,10.53%,1.32%). This relation was analysed with Chi-square test and it was not significant(Person's chi square value 1.748, df-6, P value – 0.94 ).

shows the correlation of age and aesthetic management.

The study results were similar to the results of Mon Tin Oo et al which concluded that age is not associated with satisfaction with dental appearance suggesting that dental appearance is equally important in all the ages (Tin-Oo, Saddki and Hassan, 2011). The study results are dissimilar to the results of Akarylan et al which says age and education level had an effect on satisfaction and

received previous and desired dental treatments for improvement of aesthetics(Akarslan *et al.*, 2009).

Our study shows significant association between age and management of discolouration according to Pearson's chi square test [ P value – 0.94].

Regarding the gender and treatment preferences, male patients opted for direct veneering(7.89%), non-vital bleaching(50%), vital bleaching(15.79%) and indirect veneering(1.32%) while the percentage of female patients the who opted for non-vital bleaching were 11.84%, vital bleaching were 9.21% and indirect veneering were 3.95%. Figure 4 and table 4

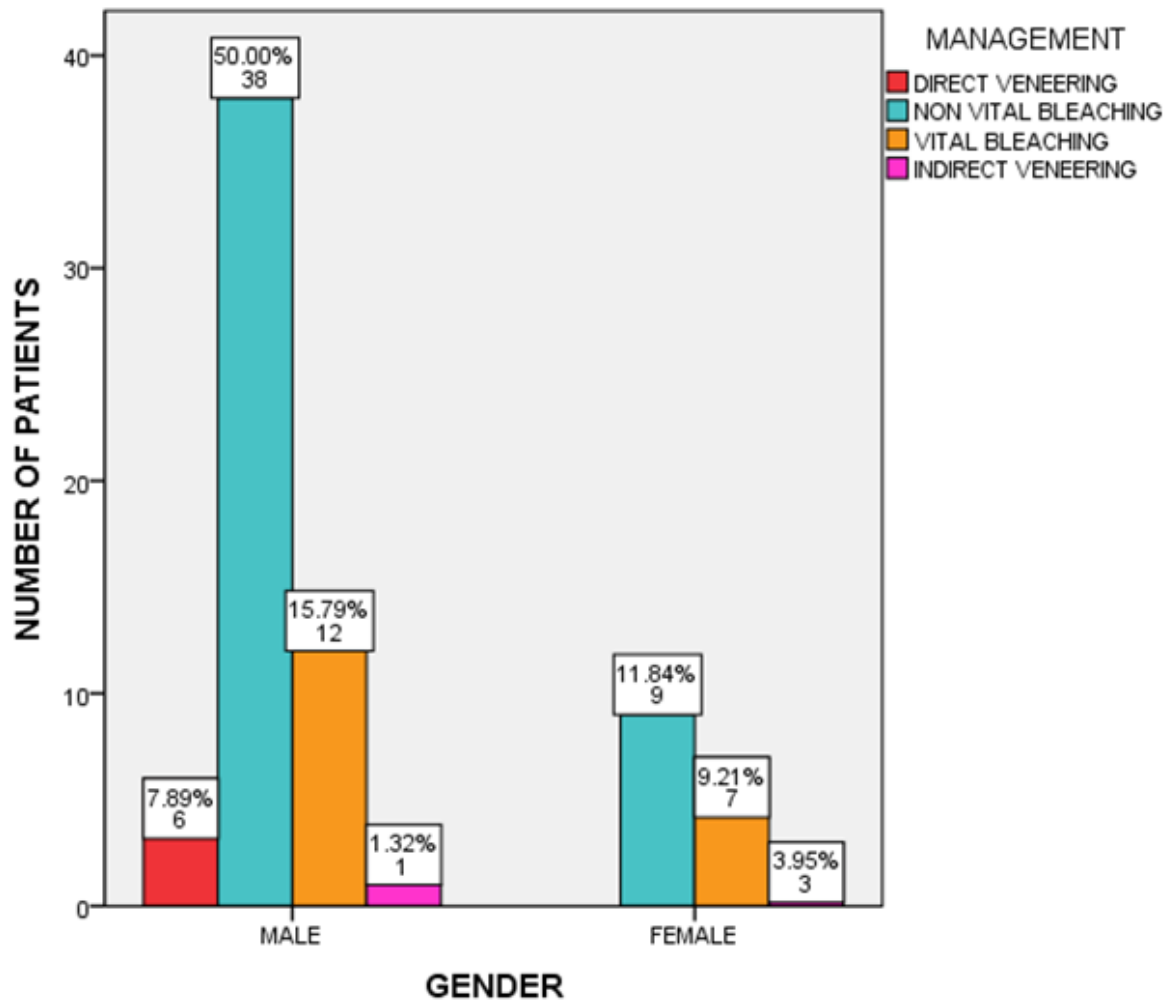


Figure 4 : Bar chart represents the correlation of gender and management of anterior discolouration of teeth. X-axis represents the gender and Y-axis represents different treatment options for management of anterior discolouration of teeth. Red colour shows direct veneering, blue colour shows non vital bleaching, orange color shows vital bleaching and pink colour shows indirect veneering. Non vital bleaching was the most common treatment preferred in both male(50%) and female(11.84%) patients. This relation was analysed with Chi-square test and it was significant(Pearson's chi square value 9.616, df-3, P value = 0.02).

shows correlation of gender and aesthetic management.

According to the study results, male patients had more aesthetic management procedures than female patients. The results are dissimilar to Mon Mon Tin Oo et al, which says dissatisfaction with tooth colour is significantly higher in female than male patients[odds ratio for 1.99, 95% confidence interval-1.1-3.50](Tin-Oo, Saddki and Hassan, 2011).

Our study shows significant association between gender and management of discolouration according to Pearson's chi square test [ P value – 0.02].

To some extent, the variations between the measurements in different studies may be attributed to the differences in measuring techniques, in the ethnicities of the populations studied, number of samples studied, gender-based variations(Jain *et al.*, 2018).



Limitations of the study include a small sample size and limited demographic area of coverage. Future scope of the study could include a multi centered study with different geographical areas and ethnicities with a wide range of population to ascertain better results. The etiological factors among various age groups for discolouration of anterior teeth are important to plan suitable treatment options and to educate the public for early interception.

## CONCLUSION

Within the limitations of the study, there was a statistical significance between anterior tooth discolouration and age(p value-0.00) the most common reason for discolouration being post root canal treatment followed by fluorosis and tobacco stains. The treatment preference across all age groups was non vital bleaching followed by vital bleaching. However regarding anterior aesthetic treatment planning gender had a significant association(p value-0.02). The number of male patients outnumbered the number of female patients seeking treatment.

## AUTHOR CONTRIBUTION

Author 1(J.Chandrapooja) carried out the retrospective study by collecting data and drafted manuscript performing the necessary statistical analysis. Author 2(Dr.Padma Ariga) aided in the conception of the topic, participated in the study design, statistical analysis and coordinated in developing the manuscript and author 3(Dr.Ganesh Jeevanandhan) aided in coordinating and developing the manuscript. All the authors have contributed in developing the manuscript.

## ACKNOWLEDGEMENT

The authors would like to acknowledge the help from the Departments of Prosthodontics and Information technology of Saveetha dental college and Hospitals and the management for their support.

## CONFLICT OF INTEREST

There is no conflict of interest.

Published by: The Mattingley Publishing Co., Inc.

## REFERENCES

1. Ajay, R. *et al.* (2017) 'Effect of Surface Modifications on the Retention of Cement-retained Implant Crowns under Fatigue Loads: An In vitro Study', *Journal of pharmacy & bioallied sciences*, 9(Suppl 1), pp. S154–S160.
2. Akarslan, Z. Z. *et al.* (2009) 'Dental esthetic satisfaction, received and desired dental treatments for improvement of esthetics', *Indian journal of dental research: official publication of Indian Society for Dental Research*. *ijdr.in*, 20(2), pp. 195–200.
3. Ashok, V. *et al.* (2014) 'Lip Bumper Prosthesis for an Acromegaly Patient: A Clinical Report', *Journal of Indian Prosthodontic Society*, 14(Suppl 1), pp. 279–282.
4. Ashok, V. and Suvitha, S. (2016) 'Awareness of all ceramic restoration in rural population', *Research Journal of Pharmacy and Technology*. A & V Publications, 9(10), pp. 1691–1693.
5. Basha, F. Y. S., Ganapathy, D. and Venugopalan, S. (2018) 'Oral Hygiene Status among Pregnant Women', *Research Journal of Pharmacy and Technology*. A & V Publications, 11(7), pp. 3099–3102.
6. ten Bosch, J. J. and Coops, J. C. (1995) 'Tooth color and reflectance as related to light scattering and enamel hardness', *Journal of dental research*. *journals.sagepub.com*, 74(1), pp. 374–380.
7. Demarco, F. F., Meireles, S. S. and Masotti, A. S. (2009) 'Over-the-counter whitening agents: a concise review', *Brazilian oral research*, 23 Suppl 1, pp. 64–70.
8. Demirel, M. G. and Tuncdemir, M. T. (2019)

- 'Influence of age, gender, and educational background on tooth color', *Nigerian journal of clinical practice*. njcponline.com, 22(2), pp. 162–166.
9. Duraisamy, R. *et al.* (2019) 'Compatibility of Nonoriginal Abutments With Implants: Evaluation of Microgap at the Implant-Abutment Interface, With Original and Nonoriginal Abutments', *Implant dentistry*, 28(3), pp. 289–295.
  10. Ganapathy, D. *et al.* (2016) 'Effect of Resin Bonded Luting Agents Influencing Marginal Discrepancy in All Ceramic Complete Veneer Crowns', *Journal of clinical and diagnostic research: JCDR*, 10(12), pp. ZC67–ZC70.
  11. Ganapathy, D. M., Kannan, A. and Venugopalan, S. (2017) 'Effect of Coated Surfaces influencing Screw Loosening in Implants: A Systematic Review and Meta-analysis', *World Journal of Dentistry*, pp. 496–502. doi: 10.5005/jp-journals-10015-1493.
  12. Goodkind, R. J. and Schwabacher, W. B. (1987) 'Use of a fiber-optic colorimeter for in vivo color measurements of 2830 anterior teeth', *The Journal of prosthetic dentistry*, 58(5), pp. 535–542.
  13. Gupta, T., Sadana, G. and Rai, H. K. (2019) 'Effect of Esthetic Defects in Anterior Teeth on the Emotional and Social Well-being of Children: A Survey', *International journal of clinical pediatric dentistry*, 12(3), pp. 229–232.
  14. Holan, G., Rahme, M. A. and Ram, D. (2009) 'Parents' attitude toward their children's appearance in the case of esthetic defects of the anterior primary teeth', *The Journal of clinical pediatric dentistry*, 34(2), pp. 141–145.
  15. Ibiyemi, O. and Taiwo, J. O. (2011) 'Psychosocial aspect of anterior tooth discoloration among adolescents in igbo-ora, southwestern Nigeria', *Annals of Ibadan postgraduate medicine*, 9(2), pp. 94–99.
  16. Jain, A. R. *et al.* (2018) 'Determination of correlation of width of maxillary anterior teeth using extraoral and intraoral factors in Indian population: A systematic review', *World J Dent. researchgate.net*, 9, pp. 68–75.
  17. Jain, A. R. and Nallaswamy, D. (2018) 'Comparison of gingival retraction produced by retraction cord and expasyl retraction systems-An in vivo study', *Drug Invention Today*, 10(1).
  18. Joiner, A. (2006) 'The bleaching of teeth: a review of the literature', *Journal of dentistry*. Elsevier, 34(7), pp. 412–419.
  19. Jyothi, S. *et al.* (2017) 'Periodontal Health Status of Three Different Groups Wearing Temporary Partial Denture', *Research Journal of Pharmacy and Technology*. A & V Publications, 10(12), pp. 4339–4342.
  20. Kannan, A. and Venugopalan, S. (2018) 'A systematic review on the effect of use of impregnated retraction cords on gingiva', *Research Journal of Pharmacy and Technology*. A & V Publications, 11(5), pp. 2121–2126.
  21. Klages, U., Bruckner, A. and Zentner, A. (2004) 'Dental aesthetics, self-awareness, and oral health-related quality of life in young adults', *The European Journal of academic.oup.com*. Available at: <https://academic.oup.com/ejo/article-abstract/26/5/507/492293>.
  22. Koleoso, D. C. U., Shaba, O. P. and Isiekwe, M. C. (2004) 'Prevalence of intrinsic tooth discolouration among 11-16 year-old

- Nigerians', *Odonto-stomatologie tropicale = Tropical dental journal*, 27(106), pp. 35–39.
23. Lui, J. L. (1987) 'Treatment of discoloured anterior teeth using a simple veneering technique', *Dental journal of Malaysia*, 9(2), pp. 19–22.
  24. Radz, G. M. (2011) 'Minimum thickness anterior porcelain restorations', *Dental clinics of North America*. Elsevier, 55(2), pp. 353–70, ix.
  25. Ranganathan, H., Ganapathy, D. M. and Jain, A. R. (2017) 'Cervical and Incisal Marginal Discrepancy in Ceramic Laminate Veneering Materials: A SEM Analysis', *Contemporary clinical dentistry*, 8(2), pp. 272–278.
  26. Selvan, S. R. and Ganapathy, D. (2016) 'Efficacy of fifth generation cephalosporins against methicillin-resistant *Staphylococcus aureus*-A review', *Journal of pharmacy research*. indianjournals.com.
  27. Solheim, T. (1988) 'Dental color as an indicator of age', *Gerodontology*, 4(3), pp. 114–118.
  28. Subasree, S., Murthykumar, K. and Dhanraj (2016) 'Effect of Aloe Vera in Oral Health-A Review', *Research Journal of Pharmacy and Technology*, p. 609. doi: 10.5958/0974-360x.2016.00116.5.
  29. Tin-Oo, M. M., Saddki, N. and Hassan, N. (2011) 'Factors influencing patient satisfaction with dental appearance and treatments they desire to improve aesthetics', *BMC oral health*, 11, p. 6.
  30. Venugopalan, S. *et al.* (2014) 'Magnetically retained silicone facial prosthesis', *Nigerian journal of clinical practice*, 17(2), pp. 260–264.
  31. Vijayalakshmi, B. and Ganapathy, D. (2016) 'Medical management of cellulitis', *Research Journal of Pharmacy and Technology*. A & V Publications, 9(11), pp. 2067–2070.
  32. Watts, A. and Addy, M. (2001) 'Tooth discolouration and staining: a review of the literature', *British dental journal*. nature.com, 190(6), pp. 309–316.